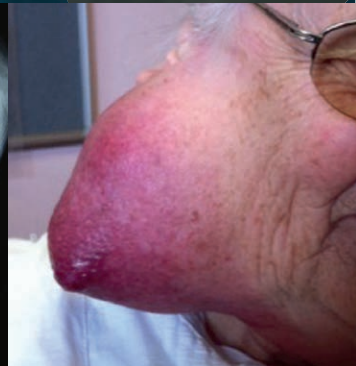
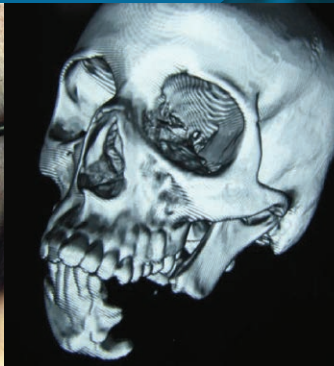
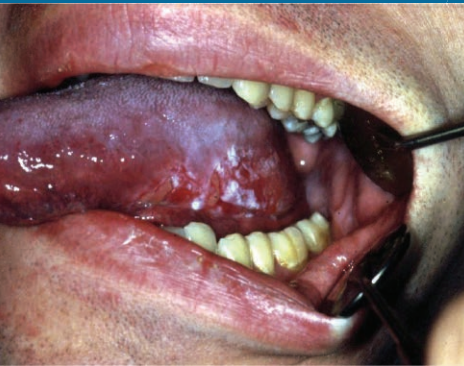**BAOMS**

THE FACE OF SURGERY

# ORAL AND MAXILLOFACIAL SURGERY

An Illustrated Guide for  
**Medical Students and  
Allied Healthcare Professionals**



**Robert Isaac  
Arpan S. Tahim  
Karl F.B. Payne  
Alexander M.C. Goodson  
Peter A. Brennan**



# **ORAL AND MAXILLOFACIAL SURGERY**

**An Illustrated Guide  
for Medical Students  
and Allied Healthcare  
Professionals**

**Robert Isaac**

**Arpan S. Tahim**

**Karl F.B. Payne**

**Alexander M.C. Goodson**

**Peter A. Brennan**

Published in 2022 by Libri Publishing

Copyright © Robert Isaac, Arpan S. Tahim, Karl F.B. Payne, Alexander M.C. Goodson and Peter A. Brennan

The right of Robert Isaac, Arpan S. Tahim, Karl F.B. Payne, Alexander M.C. Goodson and Peter A. Brennan to be identified as the authors of this work has been asserted in accordance with the Copyright, Designs and Patents Act, 1988.

ISBN 978-1-91145-086-3

All rights reserved. No part of this publication may be reproduced, stored in any retrieval system or transmitted in any form or by any means, electronic, mechanical, photocopying, recording or otherwise, without the prior written permission of the copyright holder for which application should be addressed in the first instance to the publishers. No liability shall be attached to the author, the copyright holder or the publishers for loss or damage of any nature suffered as a result of reliance on the reproduction of any of the contents of this publication or any errors or omissions in its contents.

A CIP catalogue record for this book is available from The British Library

Cover and Design by Carnegie Book Production

Libri Publishing  
Brunel House  
Volunteer Way  
Faringdon  
Oxfordshire  
SN7 7YR

Tel: +44 (0)845 873 3837

[www.libripublishing.co.uk](http://www.libripublishing.co.uk)

### **Acknowledgements**

*The chapter cover page artwork in this book by the artist Mark Gilbert has been provided courtesy of Saving Faces – the facial surgery research foundation. Additional information on this charity, the work they do and further artwork alongside interesting patient stories can be found at [www.savingfaces.co.uk](http://www.savingfaces.co.uk).*

## FOREWORD

With over 65 GMC approved specialities and 30 sub-specialities and a full medical school curriculum, the full remit and repertoire of some specialities cannot and never has featured in the undergraduate curriculum in every medical school and other related courses.

Oral and Maxillofacial Surgery (OMFS) is one of the ten UK surgical specialities and is unique in requiring both medical and dental qualifications. While some medical schools have distinct OMFS input, the majority will include this and other 'Head and Neck' teaching often delivered within Ear, Nose and Throat (ENT) content. As OMFS is a relatively new surgical specialty, with its origins from a dentistry background, many students and doctors may not be fully aware of its full remit and what it can offer patients. Some have assumed it to be 'extended dentistry' and dealing with wisdom teeth extractions and some facial trauma. However, it covers far more than that, with OMF surgeons being highly skilled in both soft tissue and bone surgery and free flap harvest from other parts of the body.

This beautifully illustrated and easy to read book should be of interest to medical students, doctors at an early career stage as well as other allied healthcare professionals who wish to gain greater understanding of OMFS, and the wider head and neck conditions that the specialty treats. It provides a wealth of information including details about skin cancer, salivary gland disease and neck lumps that many students and early career doctors might encounter as part of their practice. In addition, the book gives an insight into facial trauma and deformity, oral cancer and free flap reconstruction as well as many other areas.

I hope that this free resource, which has been funded by the British Association of Oral and Maxillofacial Surgeons (BAOMS), will provide valuable information and generate interest and enthusiasm for this important area of clinical practice.

Professor Malcolm Reed  
Dean, Brighton and Sussex Medical School  
Immediate Past Chair, Medical Schools Council



## ABOUT THE AUTHORS

### **Robert Isaac**

BDS (Hons), MBBCH (Hons), MRCS

Robert is a specialist registrar in Oral and Maxillofacial surgery (OMFS) in the Wessex Deanery. He is an elected member of the BAHNO council and has a particular interest in medical education.

Having written chapters in the 50 Landmark papers in OMFS and the upcoming Bailey and Love Essential Operations in OMFS, he hopes to increase exposure to OMFS to both dental and medical undergraduates.

### **Arpan S. Tahim**

MBBS, BSc (Hons), BDS, MRCS, MEd, PhD

Arpan is a Specialist Registrar in Oral and Maxillofacial Surgery (OMFS) in the London Deanery, and an Honorary Clinical Lecturer at UCL Medical School. He completed his PhD at the UCL Institute of Education, and has interests in academic and clinical aspects of Medical Education.

He has authored books, chapters and research articles, as well as setting up novel educational interventions and serving as conference patron for highly successful undergraduate specialty conferences.

### **Karl F.B. Payne**

BMedSci, BMBS, BDS, MRCS, PhD

Karl is a Specialist Registrar in Oral and Maxillofacial surgery (OMFS) in the West Midlands Deanery, and NIHR Clinical Lecturer at the University of Birmingham. He completed his medical training in Nottingham and Dental training in London. As an academic surgeon, Karl's primary interests are using a blood test to detect DNA mutations from head and neck cancers.

Karl has written several chapters and books in OMFS, raising awareness of the specialty at a national and international level.

**Alexander M.C. Goodson**

BSc (Hons), MBBS, BDS, FRCS (OMFS), DOHNS

Alex works as a consultant maxillofacial surgeon at Queen Alexandra Hospital, Portsmouth and is an elected fellow on the BAOMS council. Having completed his specialty training in South Wales and a post-CCT Head and Neck fellowship in Birmingham, his subspecialty interests lie in head & neck oncology, microvascular reconstruction, salivary gland disease and facial nerve injury. He has a complementary clinical research interest in the continuing development of reverse planning and additively manufactured (customised 3D-printed) CMF implants for complex reconstructions with a focus on improving surgical efficiency and quality-of-life outcomes.

He has taken an active role in raising the awareness of the specialty, having authored texts for primary care practitioners, as well as regularly teaching for the Midlands and East Deaneries and authoring texts for grass-roots trainees.

**Peter A. Brennan**

MB BS, BDS, MD, PhD, FRCS (Eng), FRCSI, Hon FRCS, FFST (Ed), FDSRCS

Peter is an NHS Consultant with a personal chair in Surgery in recognition of his extensive research and education profile. He has 700+ publications including more than 80 on human factors (HF) and patient safety.

He is editor of 6 major textbooks including the definitive two volume Maxillofacial Surgery and Gray's Surgical Anatomy.

He was 2016 President of the British Association of Oral and Maxillofacial Surgeons (BAOMS) and currently Chair of BAOMS Council.

Peter currently leads MRCS Research and has published widely on predictive validity and differential attainment in surgery examinations.

He was elected to the Royal College of Surgeons of England Council in 2020 via the general voting route, a first for OMFS.



# CONTENTS

<b>Chapter 1: Some basics</b>	<b>1</b>
1.1 Introduction	1
1.2 Examining the face and mouth	2
1.3 Some important investigations	8
1.4 The trauma patient	10
<b>Chapter 2: Frontal bone, cranium and orbits</b>	<b>13</b>
2.1 Introduction	13
2.2 Anatomy	14
2.3 Surgical access	16
2.4 Traumatic injuries to the frontal bone	17
2.5 Craniofacial surgery	19
2.6 Orbital fractures	24
2.7 Orbital compartment syndrome	25
2.8 Skin cancers	25
2.9 Closing comments	27
<b>Chapter 3: Nose and sinuses</b>	<b>29</b>
3.1 Introduction	29
3.2 Anatomy	30
3.3 Fractures	31
3.4 Bleeding	35
3.5 Dental pathology	37
3.6 Skin cancers on the nose and cheek	38
3.7 Closing comments	39
<b>Chapter 4: The jaws</b>	<b>41</b>
4.1 Anatomy and embryology	41
4.2 Fractures of the mandible and midface	42
4.2.1 Mandibular fractures	42
4.2.2 Midface fractures	45

4.3 Jaw deformity	50
4.3.1 Assessment	50
4.3.2 Examination	50
4.3.3 Treatment	52
4.4 The temporomandibular joint (TMJ)	54
4.4.1 Anatomy	54
4.4.2 Examining the TMJ	54
4.4.3 Temporomandibular joint dysfunction (TMJD)	54
4.4.4 TMJ dislocation	57
<b>Chapter 5: The mouth</b>	<b>59</b>
5.1 Anatomy	59
5.2 Ulcers and patches in the mouth	60
5.2.1 Suspicious ulcers	61
5.2.2 Benign mouth ulceration	61
5.2.3 Recurrent ulceration	62
5.2.4 Patches	63
5.3 Lumps and swellings in the mouth	68
5.4 Oral cancer	71
5.5 Dental surgery	77
5.6 Cleft lip and palate	79
<b>Chapter 6: Salivary glands, the facial nerve and facial pain</b>	<b>83</b>
6.1 Anatomy	83
6.2 Salivary pathology	85
6.2.1 Salivary tumours	85
6.2.2 Obstructive disease	88
6.2.3 Trauma	90
6.3 Facial pain	92
6.3.1 Temporomandibular disorder	92
6.3.2 Trigeminal neuralgia	92
6.3.3 Atypical facial pain and burning mouth syndrome	93
6.3.4 Post herpetic neuralgia	94
6.4 Facial palsy	95

---

<b>Chapter 7: Soft tissues and the neck</b>	<b>99</b>
7.1 Facial lacerations and neck wounds	99
7.1.1 Simple soft-tissue lacerations/wounds	99
7.1.2 Deep soft-tissue injuries	100
7.1.3 Bites	104
7.2 Neck lumps	105
7.2.1 Inflammatory including tissue space infections	105
7.2.2 Congenital	107
7.2.3 Neoplastic	112
<b>Chapter 8: Skin pathology and aesthetic surgery</b>	<b>119</b>
8.1 Skin cancer	119
8.1.1 Malignant melanoma	119
8.2 Non-melanoma skin cancer (NMSC)	123
8.3 Benign skin tumours	127
8.4 Aesthetic skin surgery	128
<b>Chapter 9: Oral and maxillofacial surgery – career and research opportunities</b>	<b>133</b>
9.1 Introduction	133
9.2 Career pathway	134
9.3 Research	135
Index	136



## PREFACE

Oral & Maxillofacial teams encounter Medical Students in a variety of settings ... commonly in the operating environment when a clinical student is attached to an anaesthetist. With complex procedures, after a period learning about induction agents, anaesthetic techniques, ECG rhythms, and fluid balance the curious might just wander up to the “top end” and become either impressed or otherwise at just what is going on.

Some students have exposure to OMFS through Emergency Dept traffic, or elect a Student Selected Module. A few already have an indication of interest -but for the majority the actual substance of seeing OMFS in action will be very limited.

Compared to other Specialties, curriculum coverage of this, one of the ten recognised surgical specialisations is very scanty in many Medical Schools - or even nil.

The British Association of Oral & Maxillofacial Surgeons funded this book as a way to widen awareness and give students, destined to become clinicians in a wide variety of areas very distant from OMFS, sufficient background knowledge of the conditions, injuries and diseases of the Oral Cavity, Jaws, Face and Neck. Between 4–12 % of all ED presentations may be related to facial injuries or emergencies, & OMFS plays a pivotal role in the multidisciplinary care of Head & Neck Cancer and Growth Disorders / Deformities.

As you read it I hope it imparts a basic grasp of what OMFS is, what it does and what this fascinating discipline deals with. I hope it equips you to deal with common presentations – and recognise the urgent. As with all texts, as soon as published it will need updating so I know the authors will value and make use of any feedback. I genuinely hope it at least triggers recognition & acknowledgement of the importance in care provision of my chosen Specialty.

**Austen SMITH**

**60th President, BAOMS**



*A man with deposits of osteosarcoma in the mid-facial skeleton.*

# CHAPTER I: SOME BASICS

## I.1 INTRODUCTION

Oral and maxillofacial surgery (OMFS) originally developed during the middle of the twentieth century, when dental surgeons began to apply their knowledge of the oral cavity and its surrounding tissues to treat military personnel who had sustained potentially devastating facial injuries during various conflicts including the Second World War.

Ever since, the remit of the specialty, and the range of various pathologies within it, has become increasingly diverse. As cases in the specialty became more complex, it was clear that in addition to a detailed knowledge of the oral cavity and facial skeleton, a firm grounding in the principles of both medicine and surgery was required to best manage these patients. In the late 1980s dual qualification in both dentistry and medicine became mandatory.

Many medical students may not have heard of OMFS, let alone become interested in finding out more about it, or even considered it as a potential career. It is unusual to find it explicitly ear-marked in medical school curricula, and many medical students, doctors and institutions have the misguided perception of the specialty as merely 'a branch of dentistry'. Yet as with all surgical specialties, OMFS shares a tremendous amount in common with the other specialties across medicine and surgery.

In this short book, we introduce you to OMFS, highlighting the overlap it shares with the medical and surgical principles that you will have come across during your training to date. We will take you through the different regions of the face and the different pathologies that patients present with, and introduce you to the ways that OMFS can manage them. While it is by no means exhaustive in its scope, and cannot include all the pathology encountered in this complex anatomical region, we hope this book will inspire you to find out more about the problems that patients can develop in this region of the body. The impact that disease and treatment in this area can have on patients and their families cannot be underestimated, as it is difficult to conceal from the outside world. We hope that the information and knowledge in this book will be useful for all students, whatever specialty or branch of medicine you decide to pursue – whether that be in general practice, medicine, one of the surgical specialties, or even perhaps, OMFS itself!

### 1.2 EXAMINING THE FACE AND MOUTH

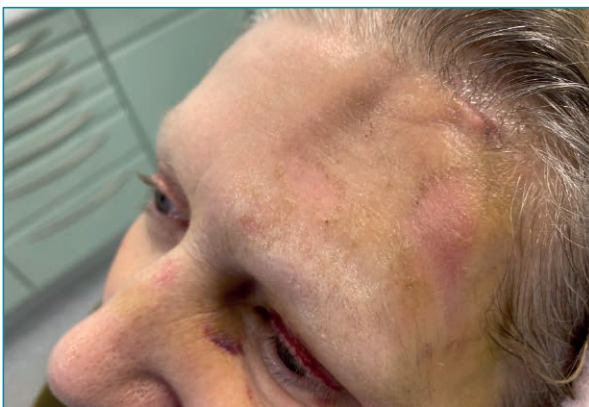As with all medical and surgical presentations, the cornerstone of management of oral and maxillofacial pathology lies in obtaining a thorough history and examination. One of the challenges to examining the head and neck region is the need for a flexible approach. Your examination is often tailored to the situation, or the information you have picked up from your patient during the history. Similarly, how you examine a trauma patient might appear very different to how you examine a patient with a parotid swelling. However, the following framework should act as a foundation of general principles that you can adapt as you gain more experience.

Many clinical examinations begin by stressing the importance of noting any abnormalities affecting the head and neck. Building on that, we shall take you through a simple examination of the facial skeleton, the dental hard tissues, the oral soft tissues and the neck.

#### Facial examination

Simply observing the face at rest allows you to assess for facial asymmetry arising from, for example, facial swellings or muscle weakness. You can make a note of any lesions, bruising or lacerations. It is also useful to see how the jaw opens and closes – which reveals important information about the muscles of mastication and the jaw joint itself. For example, patients might show painful or restricted mouth opening, or even deviation of the jaw to one side as they open.

It is also useful to screen the eye – often by checking its gross appearance, the symmetry with the other eye, the pupillary response and the range of eye movements.



*Figure 1.1: Simply examining the patient at rest can help identify obvious deformity. This patient presented with an obvious depressed left frontal bone. Picture courtesy of Lieutenant Colonel Johno Breeze*



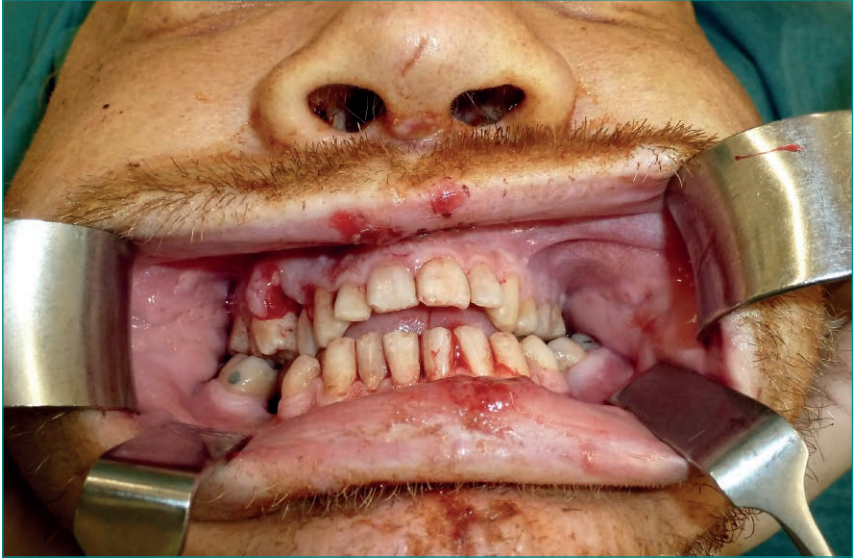You can palpate the prominences of the bony skeleton – the orbital rims, the nasal bones, the cheeks (zygoma), the temporomandibular joints (TMJ) (where you can over feel crepitus in an abnormal jaw joint) and the mandible itself. As you feel, you want to note if the area is tender, or if there is an underlying bone step that might suggest a facial bone fracture. Sometimes useful information is gained by feeling the bones inside the mouth. For example, midface fractures can often be detected by simply grasping the maxilla on either side of the upper teeth and feeling if it is mobile! As part of the palpation process, remember to check the three divisions of the trigeminal nerve (sensation to the upper, middle and lower parts of the face, and motor supply to the masticatory muscles).

### Intra-oral examination

Generally, the oral cavity can be examined without any specialist equipment, but it is imperative to have good lighting, and useful to have either a wooden tongue spatula or a dental mirror to hand.

An adult with a full dentition will have 32 teeth. These are divided into four quadrants, each containing from the midline outwards: a central incisor, lateral incisor, a canine, two premolar teeth and three molar teeth. The last of these molar teeth are often called wisdom teeth, but can be absent in some patients. Depending on the nature of the presenting complaint, important things to assess in a patient's teeth are:

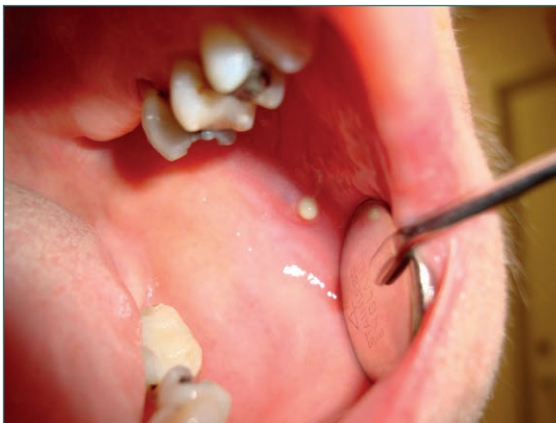- a) Any significant dental decay (or caries) – often in the form of physical defects on the teeth or brown discolouration.
- b) The presence of plastic (usually white) or metal fillings and crowns.
- c) Any mobility of the teeth, which can be done by simple palpation.
- d) Any tenderness to percussion (often done by tapping the top of the tooth with an instrument; if this is painful, it often indicates inflammatory pathology at the tip of the tooth root).
- e) Any discharging sinuses on the gums, which are a sign of chronic dental infection.
- f) How a patient's teeth bite together (also called their *dental occlusion*) as they dynamically open and close their jaw. As an example, patients with mandibular fractures often report a change in their bite, as the continuity of their dental arch is disrupted. Often you will see a gap between their teeth, or a step in their occlusion.



*Figure 1.2: This gentleman presented with an altered occlusion. Notice how his front teeth are wide open, despite biting on his posterior teeth. This is called an anterior open bite or AOB. This is commonly seen in patients with Le Fort fractures. Picture courtesy of Mr. M. Ethunandan*

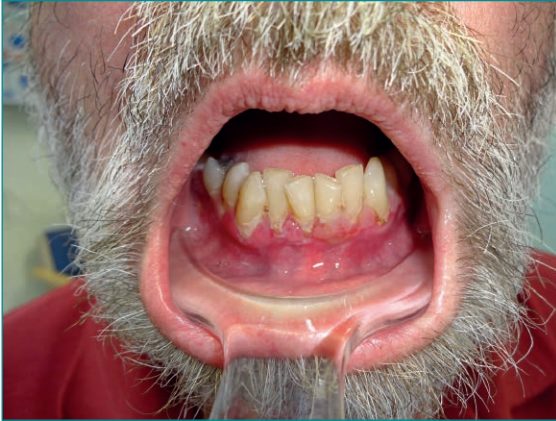It is important to systematically assess the mucosal surfaces. These areas include:

- The buccal mucosa (inner lining of cheek), including the opening of the parotid duct opposite the upper second molar



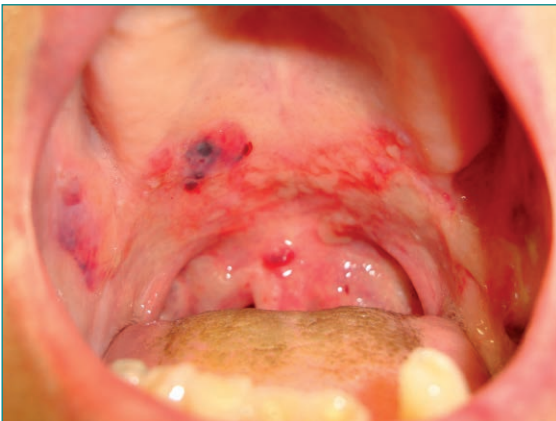*Figure 1.3: The parotid duct opens in the buccal mucosa opposite the upper second molar. Here it can be seen to discharging frank pus. This is usually indicative of parotitis. Picture courtesy of Mr. S Walsh*

- The labial mucosa (inner surface of lips)
- The lips themselves, including the presence of any numbness/altered sensation
- The gingival surfaces (gums) – including looking for gum boils (sinuses) as mentioned above



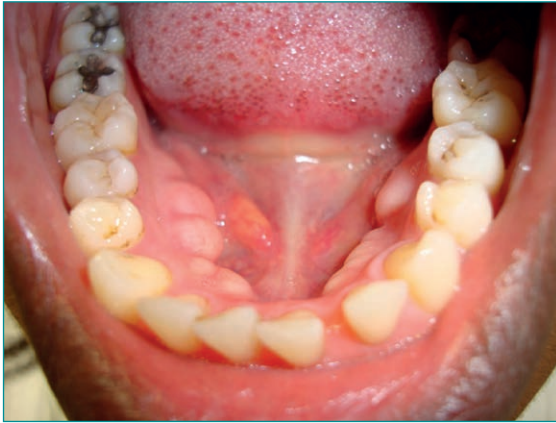*Figure 1.4: You can see that the gingivae of the lower front teeth looks acutely inflamed, with evidence of desquamation or 'sloughing'. This patient was being treated for pemphigus, a blistering condition. Picture courtesy of Mr. S. Walsh*

- The hard palate
- The soft palate



*Figure 1.5: Here at the junction between the hard and soft palate, the patient presented with acute blistering. Notice on the right soft palate some of the blisters look like they are blood filled. This was mucous membrane pemphigoid. Picture courtesy of Mr. S. Walsh*

- The tongue (dorsal surface, lateral border and ventral aspect)
- The floor of the mouth



*Figure 1.6: This patient presented with a mass in the floor of the mouth. This was later found to be a salivary stone, which is just visible beneath the mucosal surface. The patient also presented with mandibular tori, bony exostoses that will be covered later in the book. Picture courtesy of Mr. S. Walsh*

- The oropharynx
- The retromolar region (area of mucosa just behind the last standing molar tooth).

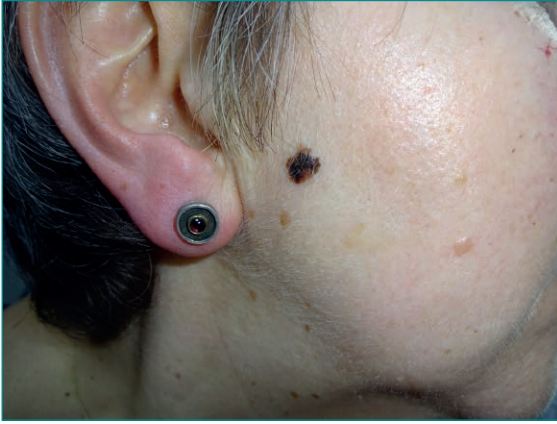As with any lump or bump, any lesion (for example a swelling or ulcer) found in the mouth should be assessed to establish its site, size, shape, colour, border and for the presence of any associated (cervical) lymphadenopathy.

### Neck examination

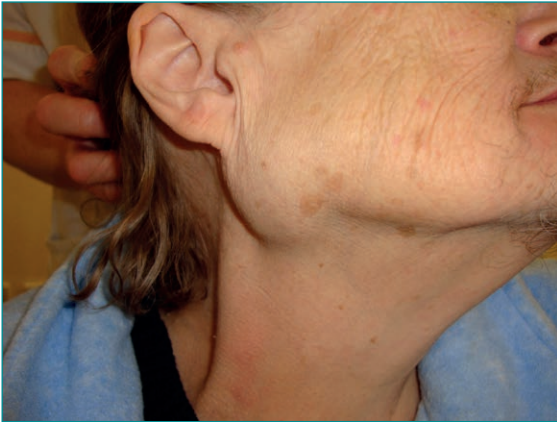The principles of a good neck examination will be familiar, and the standard inspection and palpation sequence should be followed. Observation might highlight any areas of concern and examination of lumps and lesions can be described in terms of their site, size, shape, colour, consistency, the nature of their borders, and trans-illuminescence (though rarely used in the head and neck), and assessed in relation to swallowing and tongue protrusion.

If a neck examination reveals lymphadenopathy, it is imperative to examine the skin, oral cavity, nose and face for potential sources of malignancy, and where appropriate, the other lymph-node sites (axilla, groin) and abdomen for signs of other lymphadenopathy or hepato-splenomegaly.

Of course, depending on your findings, you might need to carry out more detailed examinations of particular areas – for example, the eye, ear or cranial nerves. However, the examination framework above will hopefully be useful to help you better understand the information in the next chapters.



*Figure 1.7: A patient presented with a change in a mole. Excisional biopsy identified this as malignant melanoma. Whilst less common than other forms of skin cancer, melanoma can present with lymphadenopathy in the head and neck. Picture courtesy of Mr. S. Walsh*

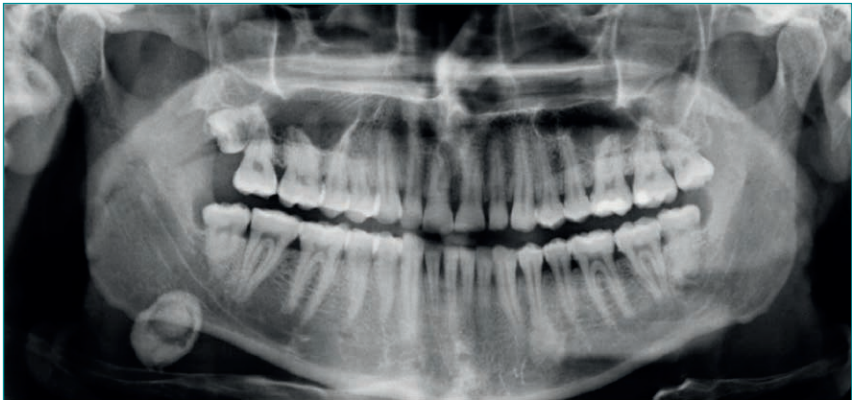

*Figure 1.8: This patient was referred in with a right neck lump. A mass was identified in the right tail of the parotid. Most parotid masses are benign (see later in text). Picture courtesy of Mr. S. Walsh*

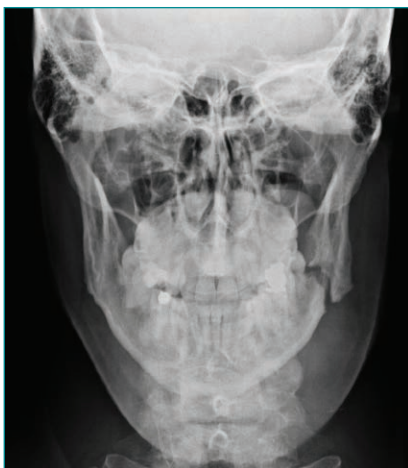### 1.3 SOME IMPORTANT INVESTIGATIONS

Depending on your history and examination findings, further information is often gained through a variety of further investigations, ranging from simple bloods tests to complex forms of imaging.

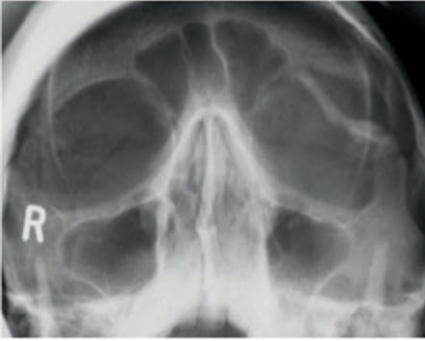
Head and neck imaging is complicated to interpret, particularly as medical students tend to be unfamiliar with both dental and facial anatomy. Below are examples of the three most common forms of plain radiograph image that help us better investigate the facial skeleton.



*Figure 1.9: This is a very common radiograph used in OMFS. It is called an orthopantomogram. It is a panoramic radiograph of the maxilla and mandible, showing all of the teeth, skeletal structures, maxillary sinuses and temporomandibular joints. It is useful for assessment of dental caries, abscesses, potential trauma or, as in this example, identifying submandibular stones. Picture courtesy of Mr. S. Walsh*

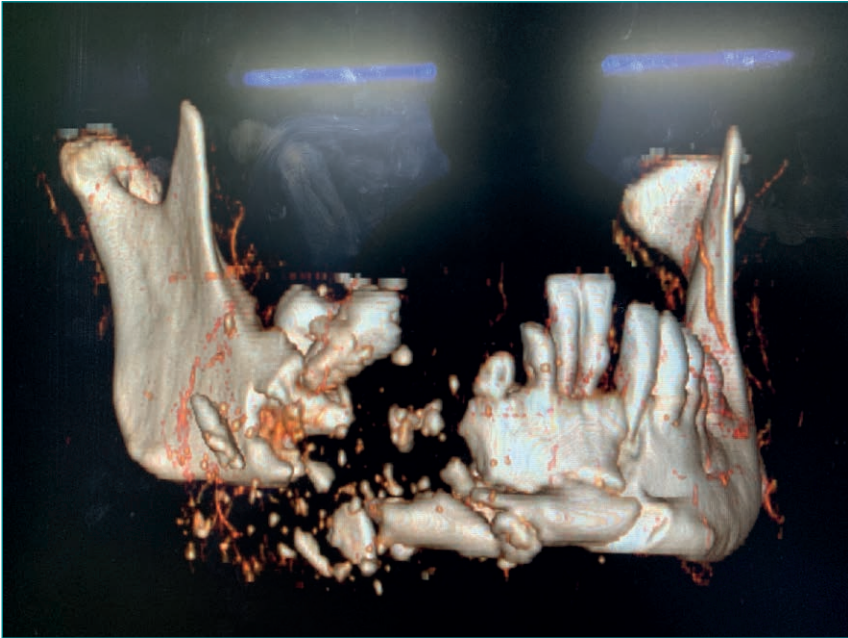


*Figure 1.10: This is a 'PA mandible'. This, when combined with an OPG, can help identify fractures of the mandible. Here a fracture of the left angle of the mandible can be seen.*



*Figure 1.11: Occipitomental radiographs, commonly known as 'facial views', are useful for the assessment of the midface and peri-orbital regions in trauma patients. They can be challenging to interpret on first view, but the key is to draw a line down the middle of the face and to look for symmetry – or in this case, asymmetry! If you compare the right superior orbital rim with the left, you can see this patient has a left supra-orbital rim fracture involving the roof of the orbit. Picture courtesy of Mr. G. Bounds*

However, over recent years, access to facial CT scans and, in particular, the ability rapidly to create, and then manipulate, 3D reconstructions for various facial structures have become extremely useful, both in diagnosis, surgical planning and, of course, helping patients understand their own injuries.



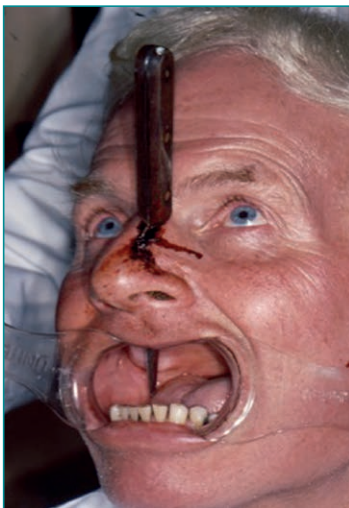*Figure 1.12: This is a 3D reformatted CT scan showing an extensively comminuted fractured mandible. This was sustained secondary to gunfire. Access to 3D reconstructed images allows for early assessment and treatment planning. Picture courtesy of Lieutenant Colonel John Breeze*

### 1.4 THE TRAUMA PATIENT

While the incidence of both military and civilian wartime facial injuries has decreased, management of the trauma patient – usually due to interpersonal violence or road-traffic accidents – continues to represent a significant workload for an oral and maxillofacial surgeon. It is useful to appreciate the role we play in the overall management of these patients.

As with all trauma patients, patients with facial trauma should be managed as per the Advanced Trauma Life Support (ATLS) algorithm (ABCDE: airway, breathing, circulation, disability, exposure), centred on quickly identifying and managing life-threatening injuries. Certain facial injuries are picked up during the primary survey and as such warrant immediate intervention. These usually take place alongside the rest of the trauma team, in an effort to stem major bleeding (for example in significant midface injuries) or maintain a threatened airway, using a surgical airway such as an immediate/emergency cricothyroidotomy (in a patient for whom emergency intubation fails and cannot otherwise be ventilated) or elective tracheostomy (for a medium-term surgical airway).

Another important life-altering post-traumatic injury relates to bleeding behind the eye – a retrobulbar haemorrhage, which, unless treated urgently with a surgical decompression via a lateral canthotomy and cantholysis, can lead to blindness. Fortunately, this type of haemorrhage is rare, but it is an OMFS emergency.



*Figure 1.13: Approaching all trauma patients using ATLS principles is essential. Despite the dramatic presentation of this patient, considering the patient's airway, breathing and circulation is a cornerstone of managing this patient. Picture courtesy of Mr. G. Bounds*



Once these injuries have been addressed, patients are then assessed in a secondary survey, where it is more common to identify many of the typical facial injuries one would sustain in a traumatic event – fractures to the facial skeleton, lacerations, muscle and nerve injuries or dental trauma.

Assessing a trauma patient can be daunting. The patient, if conscious, can be highly distressed, injuries can appear drastic and it is easy to get lost! It is therefore even more important to be systematic. The framework laid out in this chapter will help you order your thoughts.



*A twelve-year-old girl with a right anterior cranial fossa neurofibroma.*

# CHAPTER 2: FRONTAL BONE, CRANIUM AND ORBITS

## 2.1 INTRODUCTION

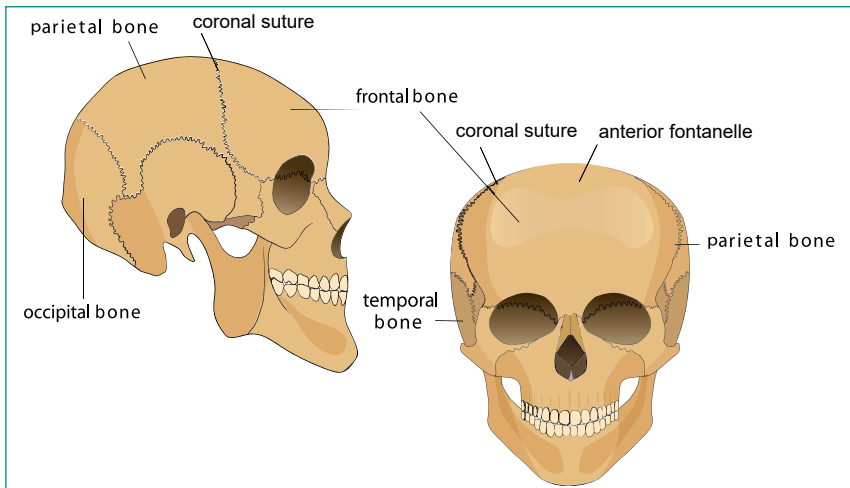
We begin at the very top, where the frontal bone that makes up the forehead forms the anterior aspect of the cranium. There are key vital structures in this region, namely the brain and the orbits, but also remember over and around these are bones, air-filled sinuses and spaces, soft-tissue structures (muscles and ducts), nerves, fat and skin. Importantly, abnormalities of the various structures within this region can present throughout life, from neonates to the very elderly.

## 2.2 ANATOMY

A brief understanding of some of the key anatomical structures will help you make sense of the pathology we encounter in this region. Starting deep, of course, is the brain, separated anteriorly from the outside world and the orbit by the frontal bone. Within the frontal bone is the frontal sinus – an air-filled cavity lined with respiratory epithelium. The significance of this is that it produces mucous, which in turn drains into the nasal cavity through the fronto-nasal duct.

The rest of the bony structure of the orbit is predominantly by the zygoma laterally and the maxilla inferiorly. The sphenoid bone importantly separates the orbit from the intracranial cavity, but allows several important structures (e.g. some cranial nerves) to pass through it into the orbit. The orbital cavity contains a number of important structures including the globe and optic nerve, the six extraocular muscles and orbital fat, which are suspending by a network of ligaments.

Importantly, the development of the bony structures of the forehead and anterior skull are related to the other bones of the skull and sutures which separate them. Like tectonic plates in geography, as the brain grows in early life, it pushes these flat bones apart at the suture lines and new bone develops in the space. Premature closure of these sutures leads to abnormal skull growth, leading to changes in the shape (and function) of the structures in this region.



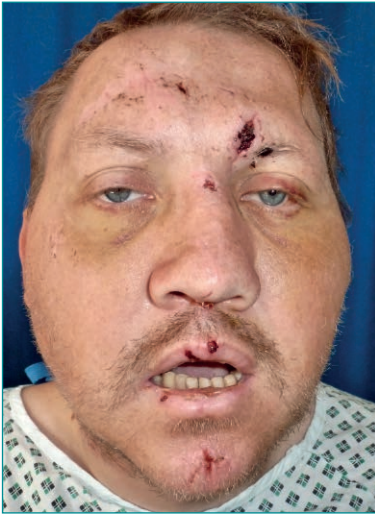*Figures 2.1 & 2.2: At birth the vault of skull is created by a number of flat bones, separated by sutures. Where two or more sutures meet are fontanelles. Premature closure of these sutures and fontanelles can result in impaired craniofacial development.*

Covering the bone is a layer of periosteum and muscles. The main muscle of the forehead is the frontalis muscle, which thins as you move superiorly, forming an aponeurotic layer in the scalp, which then envelops the occipital muscle posteriorly. This layer also continues inferiorly and links to the other muscles of facial expression. Laterally on the forehead is the temporalis muscle, the margin of which you can feel if you clench your teeth and palpate the lateral aspect of your forehead. This lateral aspect of the forehead is an important area, because here the temporal branch of the facial nerve runs very superficially. As a result, it is prone to injury in this area, via a number of pathological or iatrogenic mechanisms.

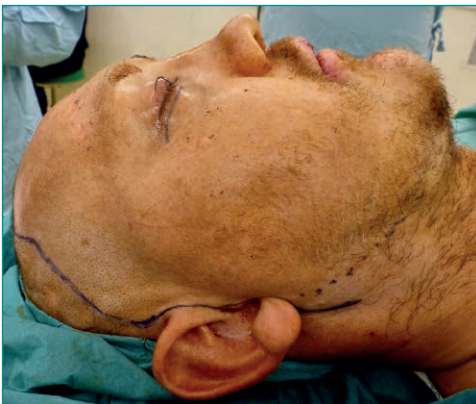Other important nerves and vessels in the area are placed supero-medially around the orbit – in particular, the supratrochlear artery, which supplies the skin over the paramedian forehead, and which becomes very useful in facial reconstruction in the form of a pedicled ‘paramedian forehead flap’ (for reconstructing the tip of the nose, for example).

### 2.3 SURGICAL ACCESS

Perhaps one of the most dramatic features of operating on this region is recognising the key structure of the scalp: its fantastic blood supply. Using coronally orientated incisions, scars can be hidden posteriorly, in the hair-bearing areas, thereby avoiding important soft-tissue structures and avoiding unsightly scars. The scalp can then be peeled forward and backward, allowing access to the bones of the skull. Furthermore, the in-depth knowledge of the different layers that the temporal branch of the facial nerve branch runs allows us to expose the forehead, temple region, orbit and zygomatic arch, while minimising any risks to the facial nerve itself. Once these bony structures are exposed, the underlying pathology can be addressed in whatever form is required.



*Figure 2.3: This gentleman presented with multiple fractures to the facial skeleton. This is often described as 'pan-facial fractures'. Picture courtesy of Mr. M. Ethunandan*



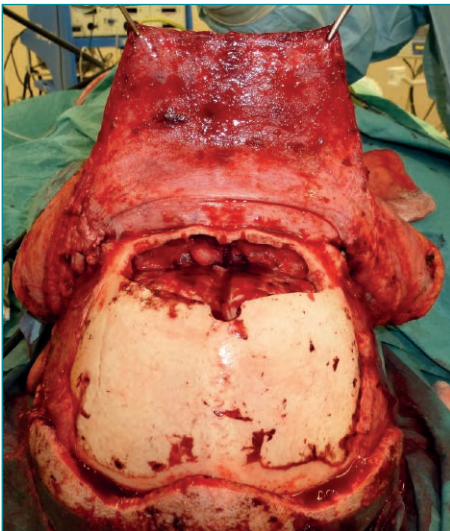*Figure 2.4: Due to its excellent vascularity, an incision can be placed in the hair-bearing regions of the scalp and the face 'peeled down' to expose the fractures using a top-to-bottom approach. This is called a 'coronal flap'. The patient was shaved moments before surgery to reduce the potential of infection. Picture courtesy of Mr. M. Ethunandan*

## 2.4 TRAUMATIC INJURIES TO THE FRONTAL BONE

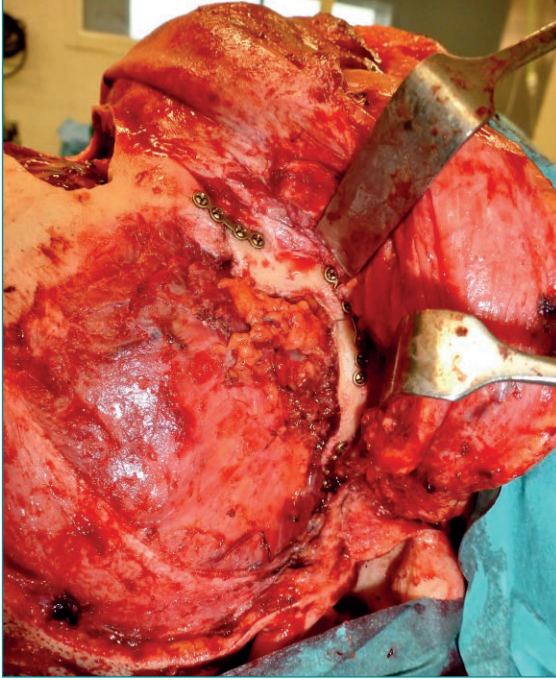
Fractures to the frontal bone, caused by blows to the forehead, are important for two reasons. Firstly, because of the prominence of the forehead and superior orbital rim, and the relatively thin overlying cutaneous tissues, they can leave marked aesthetic deformities. However, of greater concern, particularly when the posterior table of the frontal sinus is involved, they can provide a pathway for infection to spread directly into the anterior cranial fossa.

Such injuries disrupt the underlying dura. This can result in the leaking of cerebrospinal fluid (CSF), which leaks through the fracture, into the frontal sinus, through the fronto-nasal duct and then presents as CSF rhinorrhea. It is of course difficult to differentiate CSF rhinorrhea from typical nasal discharge in the trauma setting. A sample can be sent to the lab, where electrophoresis can confirm the presence of  $\beta 2$  transferrin.

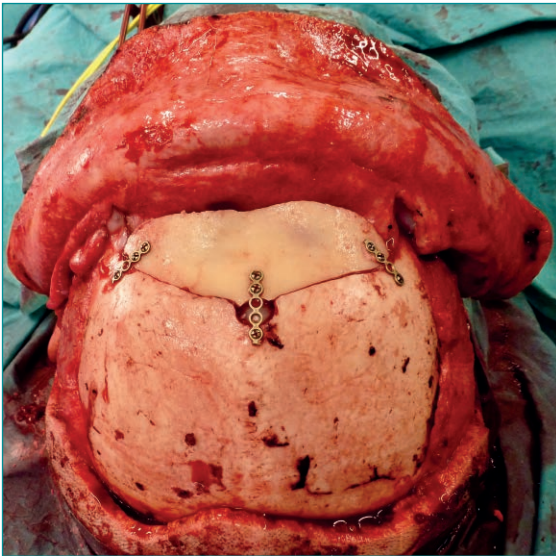
CT is the most helpful radiological investigation and allows us to analyse in detail the site and the extent of the fracture, which helps to determine the nature of the surgical procedure required. Importantly, with these injuries, the aim is to ensure the fractured frontal sinus does not lead to infection or inflammation around the brain, and to reconstruct the bony contour appropriately. Sometimes, surgical corrections require full coronal access, with craniotomies. However, in less significant injuries, fractures can be reduced and fixed endoscopically. Sometimes, the bony contour can even be camouflaged using other techniques such as fat grafting.



*Figure 2.5: As part of the pan-facial fractures, the patient presented with a depressed frontal bone fracture. A coronal flap was raised to allow access to the frontal bone and zygomatic arches. In this picture you can see into the frontal sinus. The surgeon is lifting the periosteum of the skull, otherwise known as the pericranium, which can be used to seal the frontal sinus from nasal passages. Picture courtesy of Mr. M. Ethunandan*



*Figure 2.6: The coronal flap also allows access to the supra-orbital rim and the arch of the zygoma. Here you can see where the surgeon has isolated these regions, reduced the underlying fractured bones and immobilised the bones in their correct positions with plates and screws. Picture courtesy of Mr. M. Ethunandan*



*Figure 2.7 Following this, the patient's frontal bone was placed into the correct position and immobilised or 'fixed' in this position with plates and screws. Picture courtesy of Mr. M. Ethunandan*



## 2.5 CRANIOFACIAL SURGERY

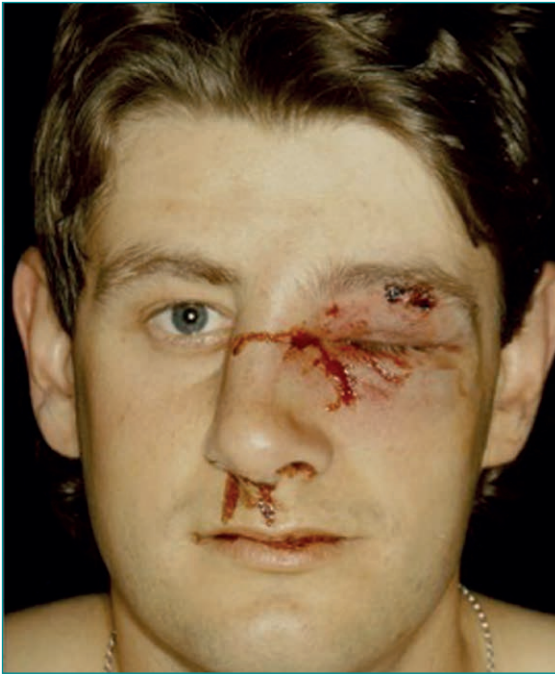Another set of pathologies are those that relate to the abnormal development of the bony structures and soft-tissue structures of the face. These are often related to the premature or incomplete fusion of various facial structures during embryonic development.

When cranial sutures fuse prematurely, it is called craniosynostosis. This restricts the growth of the cranial vault at the suture line, and instead the skull grows in different directions to accommodate the developing brain. Sometimes more than one suture is involved, and this may occur as part of a syndrome. Importantly, this premature fusion can impact the skull base and facial skeleton, leading not only to abnormally shaped skull vaults, but raised intracranial pressures, ocular problems and restricted midface growth with associated risks to the airway.

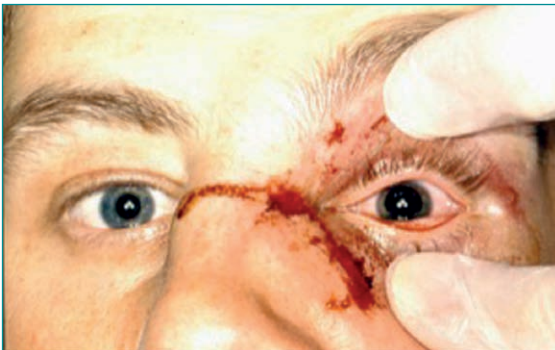Managing these patients is complex, involving a multidisciplinary team (MDT) including not only OMFS, but also our allied surgical specialties – plastic surgery and neurosurgery, and also, for example, paediatrics, speech and language therapy (SALT) and dietetics. Surgery, which is usually performed within the first year of life, often involves excision of the fused suture, but also cranial vault remodelling. In other words, cuts are made in the bony skull. The fragments are then either repositioned using resorbable (slowly dissolving) plates and screws, or they are moved more gradually through a process called distraction osteogenesis.

## 2.6 ORBITAL FRACTURES

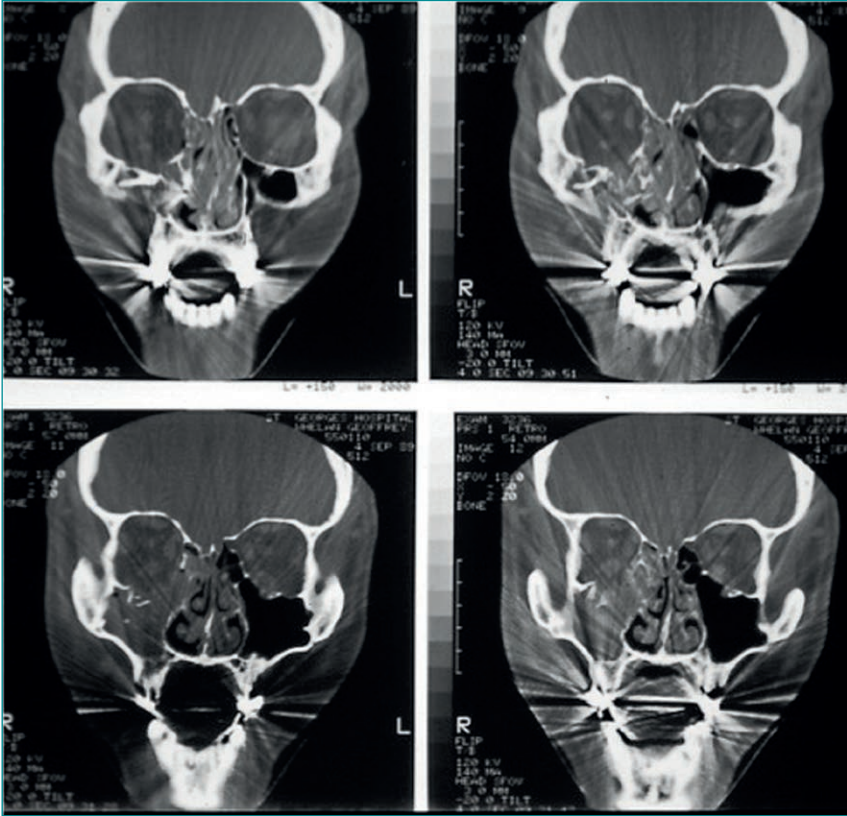
Directly inferior to the forehead are the orbits. Medial to them is the nose, inferiorly the maxilla and inferolateral are the cheek prominences of the zygoma. There are some natural weak points where the continuity of the orbital skeleton can be disrupted. Firstly, the floor of the orbit (also the roof of the maxillary sinus) is egg-shell thin. So too is the medial wall, formed by the delicate lacrimal and ethmoid bones. These areas often crumble after a blow to the region. There are other areas around the orbit which can also fracture, but we will discuss those a little later.



*Figure 2.8: This young man has been assaulted. Initial assessment of his face suggests nasal bone fractures as his nose is clearly deviating to the right. However, it is essential to open the left eye to assess for any underlying orbital trauma. Picture courtesy of Mr. G. Bounds*

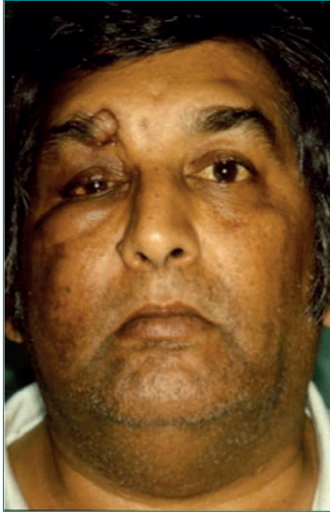

*Figure 2.9: After opening the eye, the pupils are assessed for direct and consensual light responses. Visual acuity can be crudely assessed prior to a more detailed examination for disrupted eyeball movement or diplopia. Picture courtesy of Mr. G. Bounds*



*Figure 2.10: Whilst plain film x-rays can be of use, CT scans are the gold standard for assessment for orbital fractures. Here are images of a right orbital floor and medial wall fracture. Note how clear (black) the left maxillary sinus is. The right is full of fluid (grey) and you can see part of the floor of the right orbit pushed into the sinus. Picture courtesy of Mr. G. Bounds*

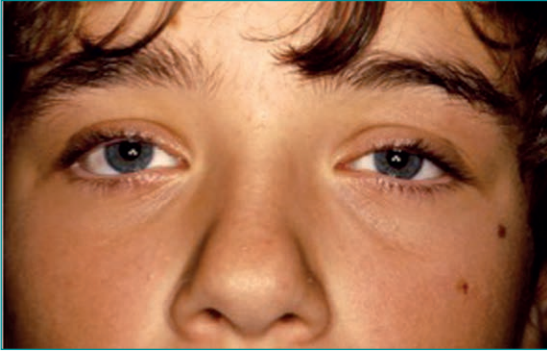It is unsurprising that a patient who has suffered a blow to the orbital region will present with swelling and peri-orbital bruising. Sometimes, the fat, or even the inferior rectus muscle, can get trapped in the fracture line, leading to a restriction in upward gaze. This often resolves as the swelling settles. However, what happens after the swelling resolves becomes most important in managing these patients – and these sequelae relate to orbital volume. By this, we mean that fractures to those bones mentioned above lead to an increase in orbital volume. In patients with more significant bony defects, this ultimately leads to a change in the position of the globe, where it either sinks back into the orbit (enophthalmos) or drops down (hypoglobus).



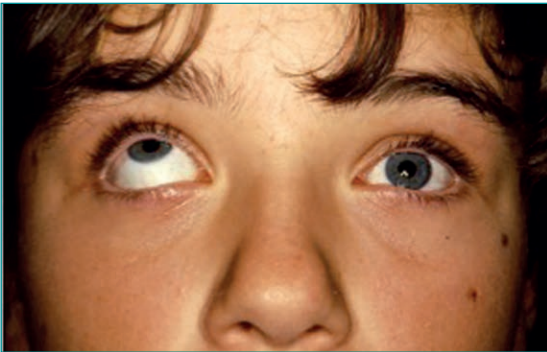*Figure 2.11: Notice how the right eye looks lower than the left. The best way to assess this is to draw an imaginary line between the two pupils. The right pupil is below this line. This is called hypoglobus. Picture courtesy of Mr. G. Bounds*

To stop this from happening, we often reconstruct these areas with prefabricated orbital titanium meshes, which support the globe in its normal position and stop it from sinking back and down. One of the commonest ways these are placed are via a trans-conjunctival approach, where the scar is hidden in the inner aspect of the lower eyelid. Here, we rely on a detailed appreciation of eyelid anatomy to carefully evert the lower lid, incise the conjunctiva, dissect our way toward the orbital rim before incising the periosteum. This allows us to gently lift the globe, to explore the orbital floor and, if needed, the medial wall, and to position the implant. This can often be done without an external scar.

Another interesting thought about orbital floor fractures relates to the differences between adult and paediatric bone characteristics. You will probably recall how adult bones tend to be more brittle, while those of children are more elastic and spring like. While adult bones tend to fracture (as described above), in children who suffer a blow to the orbital region, the bones of the orbital floor can partially break, distort and then spring back into place. In doing so, they trap the soft tissues in the fracture line. This entrapment evokes an oculo-cardiac reflex – leading to nausea, vomiting and bradycardia. Unlike the situation above, this warrants immediate attention, involving release of the tissues to prevent life-altering morbidity.



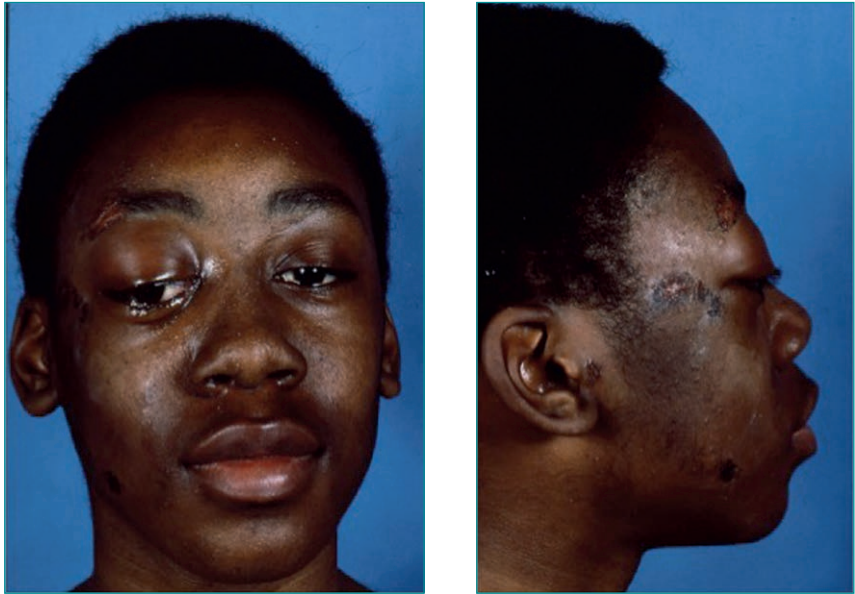*Figures 2.12 & 2.13:  
This young man on first inspection looks absolutely normal. There is no subconjunctival haemorrhage or hypoglobus. However, on moving the eye there is clear restriction of the left eye on upward gaze. This is due to muscle entrapment. This is called 'white eye orbital floor fracture' and mainly occurs in children. Picture courtesy of Mr. G. Bounds*



## 2.7 ORBITAL COMPARTMENT SYNDROME

As mentioned above, the orbit is a bony cavity with no ability to expand. The contents of the cavity are kept in place by a network of tight ligaments anteriorly. As a result, any swelling behind the eye will increase in intra-orbital pressure and compress the important neurovascular structures (optic nerve and retinal artery) there. Such a swelling is typically caused by traumatic injury, but can also be caused by neoplastic or other inflammatory processes.

The rise in intra-orbital pressure leads to disproportionate pain behind the eye, reduced and painful eye movements (ophthalmoplegia), proptosis (where the eye appears pushed out of the socket), a tense globe and reduced visual acuity.



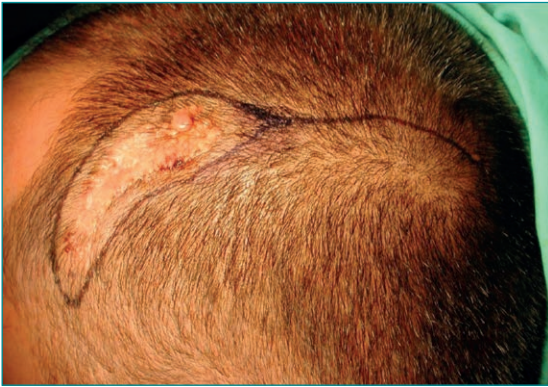
*Figures 2.14 & 2.15: This young man presented with excruciating pain from the right orbital region. Note how pushed forward his eye is. This is proptosis. He also had a progressively dilated pupil. This was retrobulbar haemorrhage and needed urgent medical and surgical intervention. Pictures courtesy of Mr. G. Bounds*

Urgent action needs to be taken to avoid permanent blindness. This takes the form of a surgical decompression, where the lateral canthus, which holds the lateral aspects of the upper and lower eyelid to the lateral orbital wall, is cut to allow the pressure behind the eye to be released.

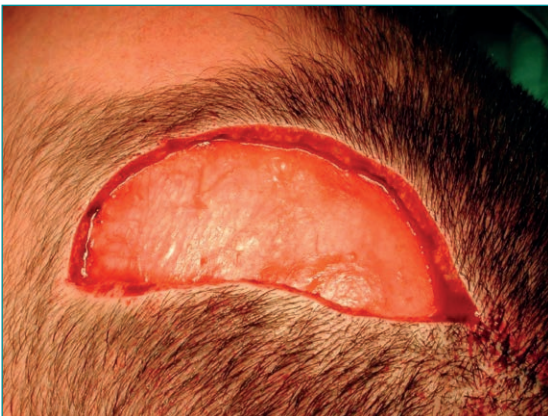## 2.8 SKIN CANCERS

The scalp and forehead are very common areas to develop cutaneous malignancies. The commonest kinds of cancers are basal cell carcinomas (BCC) and squamous cell carcinomas (SCC). These cancers can be treated with radiotherapy, but more often require surgical excision. To do so safely requires a wide local excision where the cancers are removed with a 4–6mm margin of normal-looking skin around the tumour.

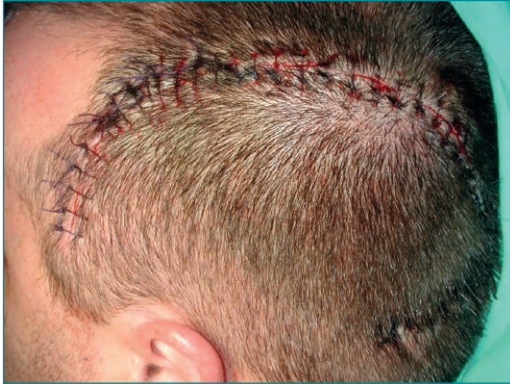Although these numbers sound small, on the forehead and scalp they can lead to considerable defects. It is often difficult to close these defects primarily, and as such, it is common to close these areas using local skin flaps, which are essentially a way of utilising the laxity in nearby skin to close the defect in such a way that limits the tension across the healing scar.



*Figure 2.16: This gentleman presented with a lesion in the hair-bearing region of the scalp. Picture courtesy of Professor P. Brennan*

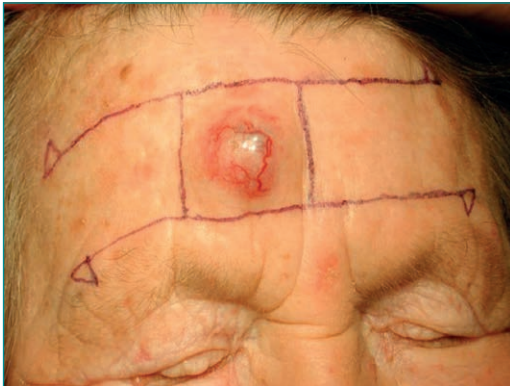

*Figure 2.17: Following excision of the lesion, he was left with a considerable defect. Picture courtesy of Professor P. Brennan*

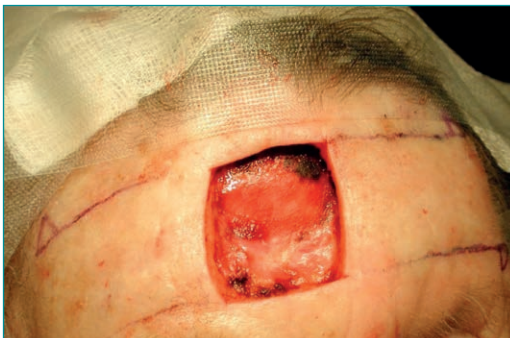

*Figure 2.18: Here a local flap was used and rotated into the defect. This allowed for 'stretching' of the adjacent skin into the defect, leaving the patient with only a linear scar that will be hidden by his hair. Picture courtesy of Professor P. Brennan*

Defects on the forehead can cause particular aesthetic compromise and patients are often worried about scarring. To minimise this, excision (and local flap reconstruction) is done in such a way that best camouflages the scars, often making use of the horizontal relaxed skin tension lines – indicated by the skin creases left by the wrinkles in the forehead. This leads to a sideways 'H'-shaped scar, which leaves the best possible scar.

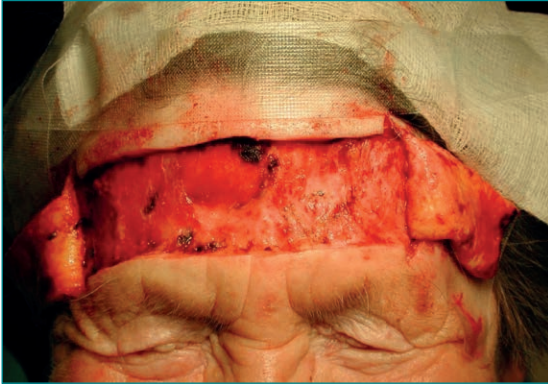


*Figure 2.19: This elderly lady presented with a cutaneous malignancy in the midline of the forehead. Picture courtesy of Professor P. Brennan*

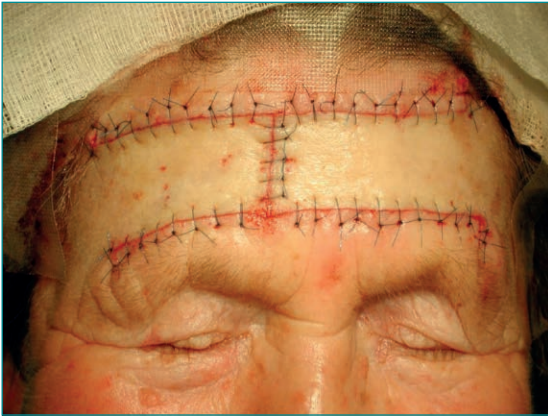

*Figure 2.20: In order to increase the chance of complete clearance of the tumour, a margin of 'normal' tissue is excised all around the tumour. This left a considerable defect that could not be closed by primary closure. Picture courtesy of Professor P. Brennan*





*Figure 2.21: A local flap was used, where our knowledge of wrinkles or relaxed skin tension lines allows us to recruit neighbouring skin into the defect whilst placing incisions in 'wrinkles'. Picture courtesy of Professor P. Brennan*

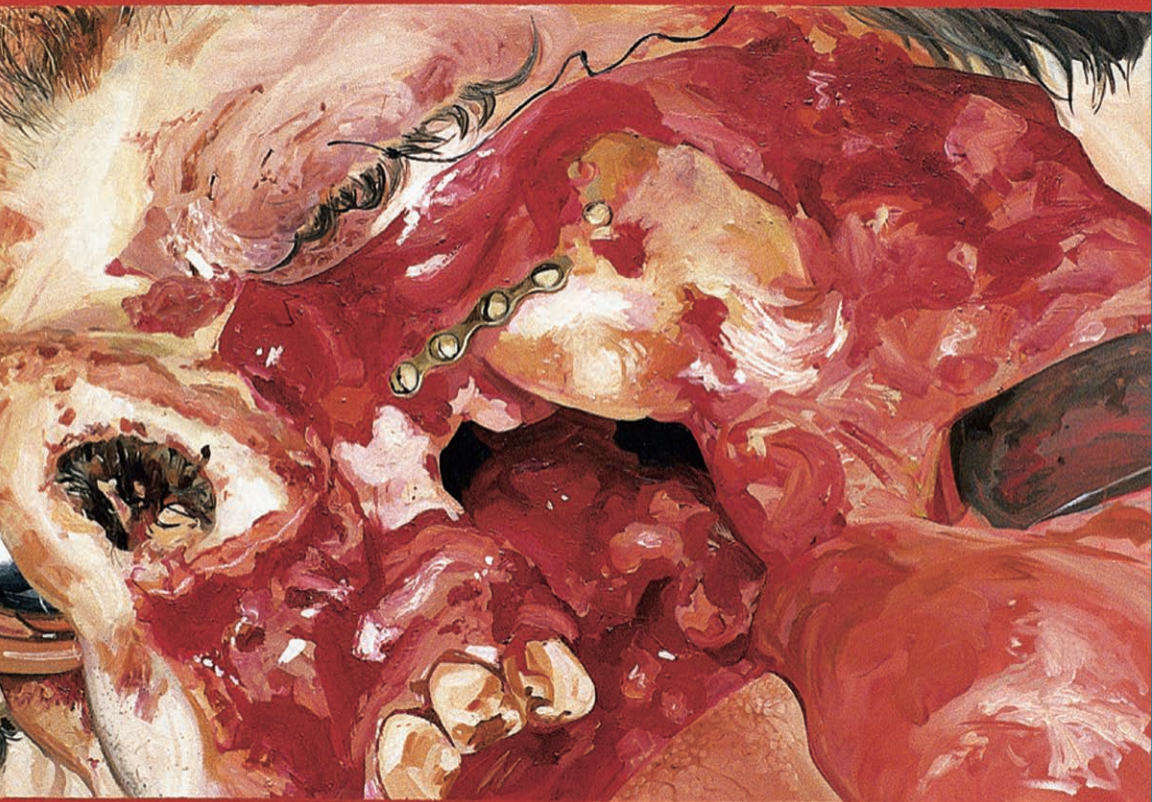

*Figure 2.22: The finished result! With time, the incisions will look like wrinkle lines on the patient's forehead. Picture courtesy of Professor P. Brennan*

In the hair-bearing area of the scalp, larger defects can also be covered by a skin graft. Biological scaffolds can also be used (for example, a porcine/bovine dermis substitute) which facilitate healing.

## 2.9 CLOSING COMMENTS

In this chapter, we hope to have guided you through some of the common problems that we encounter in the upper one-third of the face. As you will see throughout this book, problems can arise at multiple different levels or involve different tissues within the region – bone, muscle, nerves or skin. We hope you can also appreciate the range in age of patients that are treated, ranging from the paediatric neonate with a craniofacial deformity, through to the octogenarian with a cutaneous malignancy. We will build on these further through the remaining chapters.



*A patient undergoing extended maxillectomy for adenoid cystic carcinoma.*

# CHAPTER 3: NOSE AND SINUSES

## 3.1 INTRODUCTION

The air spaces in the facial region – namely the nasal cavity and the paranasal sinuses – are complex. Because of their complexity, we often find ourselves working closely with other surgical specialties – ENT surgeons, plastic surgeons, oculoplastic surgeons, neurosurgeons and ophthalmic surgeons, to name a few – to best manage the range of pathologies that arise in this region. In this chapter, we'll discuss how the oral and maxillofacial surgeon might encounter these pathologies.

### 3.2 ANATOMY

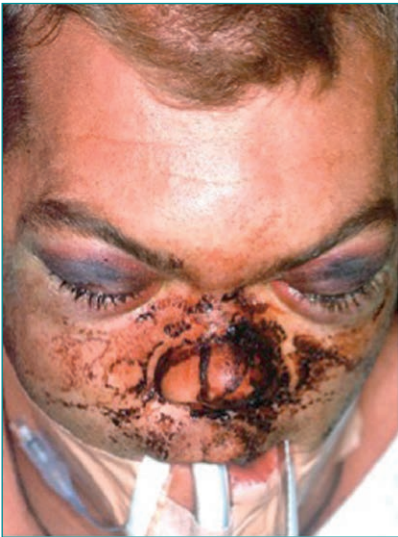The nose connects the outside world to the nasopharynx. It aids breathing and smelling. It has a rigid bony framework superiorly and a more flexible, cartilaginous framework inferiorly. Overlying this is a thin layer of muscle, subcutaneous fat and skin. The inside of the nose is divided into left and right nasal spaces by a cartilaginous nasal septum. On each lateral nasal wall are three invaginations (the inferior, middle and superior turbinates), which serve to increase the surface area of the mucosa that lines the inner surface of the nose. Between each turbinate is a space – a meatus – into which the paranasal sinuses drain. In addition, the nasolacrimal duct also drains tears from the medial aspect of the eye into the nose.

There are four pairs of paranasal sinuses – the maxillary (which is our key concern in this chapter), the frontal (which you have met already in the previous chapter), the ethmoid and the sphenoid sinuses (which lie slightly deeper behind the nose). These sinuses are surrounded by thin, egg-shell-like bone. Their purpose is not yet fully clear, but many think they serve as a physiological crumple zone, dissipating the forces around the facial skeleton to avoid significant injuries to the vital structures (eyes and brain).

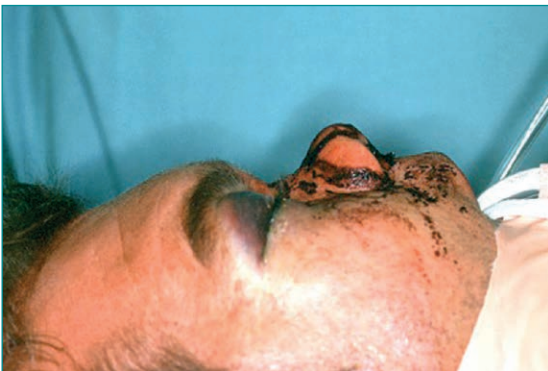There is a small hole in the front of the maxillary sinus where the infra-orbital nerve emerges. This nerve is a branch of the trigeminal nerve, and runs directly underneath the orbital floor, before emerging through the infra-orbital foramen. It supplies sensation to the cheek, lateral nose and upper teeth. When the nearby bones are fractured – for example, the roof of the maxillary sinus (or the orbital floor) – patients often report an altered sensation in the distribution of this nerve, as it has become stretched, bruised, swollen or cut.

### 3.3 FRACTURES

The nose has a prominent position on the face and so is prone to traumatic injury. Common causes of nasal bone fractures, indeed any facial bone fracture, are interpersonal violence, sports injuries and road-traffic accidents (RTAs). Sometimes patients present with isolated nasal bone fractures, but it is also common for patients to present to us with nasal fractures as part of more complex facial trauma. Here they can present alongside orbital wall fractures, zygomatic or maxillary fractures, or as part of more complicated naso-orbito-ethmoidal complex or midface fractures.



*Figure 3.1: This patient presented with significant facial trauma. He had comminuted fractures of his nasal bones, but also involving his orbital and ethmoidal bones. These are commonly called naso-orbito-ethmoidal fractures or NOE. Picture courtesy of Mr. A. Sidebottom*



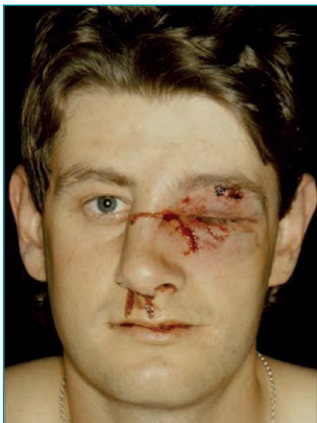*Figure 3.2: Notice from this side-on picture that you can really see how 'dished in' the bridge of the nose is. Such fractures can also cause separation of the medial canthi called telecanthus. Picture courtesy of Mr. A. Sidebottom*

Luckily, unlike the long bone fractures that orthopaedic surgeons might encounter, the physiological forces on the midface bones (such as the nasal bones, midface and zygoma) are distributed in different ways. Fractures of these bones will often heal by themselves (wherever they end up lying). As a result, not every fracture requires operative intervention, provided there is no significant visible deformity. Therefore, when patients suffer facial fractures, it is important for us to make an accurate assessment of exactly what the traumatic deformity looks like.

Due to the natural, and important, inflammatory response to any acute injury, post-traumatic swelling typically worsens over the first 48–72 hours. This makes it difficult to make an accurate assessment of any facial defect in the first few days after an injury. However, after that time, swelling begins to settle. As such, it is not uncommon for us to wait for 7–10 days after the actual injury to bones of the midface to make a decision about whether a fracture requires any operative intervention. Importantly, this time is not wasted! Aside from allowing the swelling to settle, because these fractures involve or are close to the orbit, this 10-day window is invaluable in allowing us to liaise with our ophthalmology colleagues to ensure there is no accompanying eye injury and arrange appropriate imaging.

Bones take several weeks to heal after they have been fractured. This leaves the oral and maxillofacial surgeon a window of time to correct these bony defects – to allow soft-tissue swelling to settle, but before the bones have started to remodel and heal. Therefore, when operative fixation is warranted, we aim to do this within three-to-four weeks; otherwise, the bone edges become sticky and more difficult to put back in the correct position.

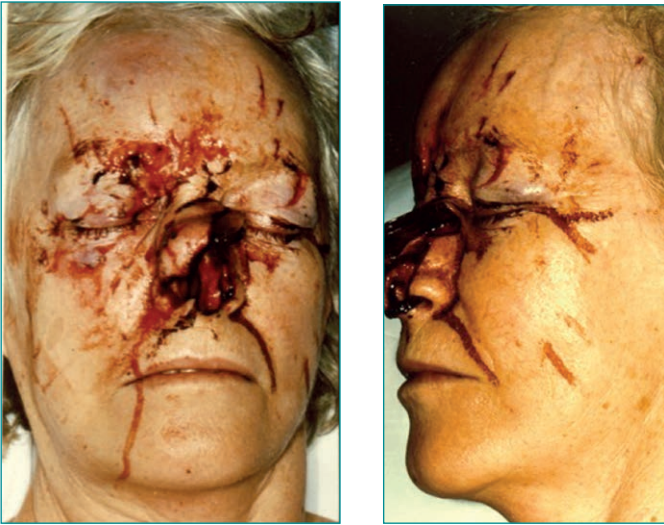
Following this, displaced nasal bone fractures are generally managed in a ‘closed’ fashion. Here, there is no incision and exposure of the bone itself.



*Figure 3.3: If this patient had no other injuries and only the obvious nasal bone fracture, he may well have been a candidate for ‘closed reduction’ or manipulation of nasal bones under anaesthesia. Picture courtesy of Mr. G. Bounds*

Instead, under general anaesthesia, the nasal bones are manipulated back into an appropriate position, and a small nasal splint is applied for several weeks to hold them in position.

In patients with more significant deformities, those with older injuries or those where a manipulation has not succeeded in appropriately realigning the nose, more complex procedures are required. This is because the traumatic injury has led to damage to the cartilaginous framework of the nose, or because the bony fragments of the nose have healed in an incorrect position and are no longer moveable by simple manipulation. Sometimes, the position of the cartilaginous framework needs to be corrected, which is called a septoplasty. Here, the deformed cartilage of the nasal septum is removed, reshaped and repositioned. Occasionally, we borrow cartilage from elsewhere – for example, the costal cartilage of a rib or ear. Sometimes, the nasal bones need to be osteotomised (i.e. re-broken), and repositioned, in what is known as a rhinoplasty. Sometimes both of these are required to correct the post-traumatic nasal defect – a septorhinoplasty.



*Figures 3.4 & 3.5: Due to the extent of the injuries sustained, this patient would have needed attention not only to the superficial structures, but also to rebuild the cartilaginous and bony skeleton of the nose. Pictures courtesy of Mr. G. Bounds*

Patients with cleft lip and palate often require similar procedures because the growth, development and therefore shape of the nose have been highly disrupted. Similarly, in other craniofacial deformities, such as those encountered in Chapter 5, when the upper jaw is moved around into its correct position, adjustments to the nasal septum and bones are often required to avoid disruption to nasal structures.

On either side of the nasal cavity are each of the maxillary sinuses. These air spaces are lined with respiratory epithelium and contained within relatively thin bone. Above the maxillary sinus is the floor of the orbit. You can feel the anterior wall just lateral to the nose, and might just be able to get to its posterolateral wall if you can get your finger anywhere beyond your upper wisdom teeth! As mentioned above, the maxillary sinus serves as a biological crumple zone – which means it often fractures during trauma to the face. As with the nose, sometimes these fractures are isolated to a single maxillary sinus wall, but often they involve one or more walls, or occur with other bony fractures.

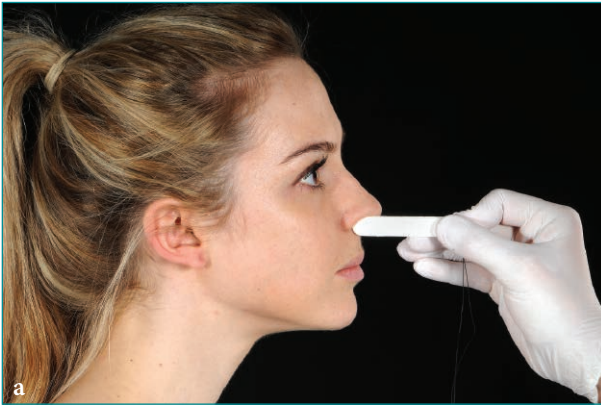Lateral to the maxillary sinus is the zygoma – the cheekbone. Like the nose, its prominence on the lateral aspect of the face leaves it prone to traumatic injury. The zygoma has a posterior extension, which forms an arch between the bones on the front of the head and those on the side of the head. This arch is a remarkable piece of anatomy that can be lifted with an instrument to effectively reposition the body of the zygoma when we repair fractures that involve the zygoma.

As you have seen throughout this book, oral and maxillofacial surgeons have unique and varied ways to access, reduce and fix facial bone fractures, to minimise conspicuous scars. We are always trying to hide scars in areas that are not usually visible – for example, in the hairline, in the mouth, in the natural skin creases and even in the conjunctiva. We can do this because the face has a wonderfully rich blood supply, and we can pull and stretch the skin in a way that is sometimes the envy of surgeons who operate on other parts of the body.

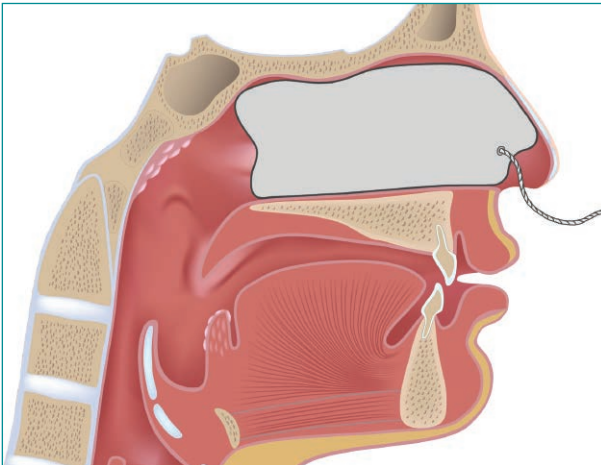


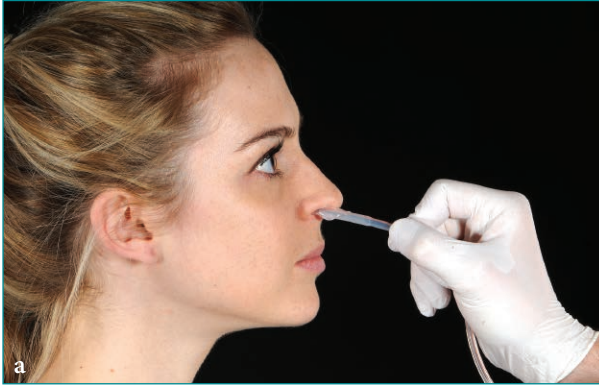### 3.4 BLEEDING

A patient with isolated nasal bleeding (epistaxis) tends to find their way to our ENT colleagues. However, it is important to realise that nosebleeds can also arise secondary to other facial injuries – in particular when there are fractures that involve the maxillary sinuses or midface. We have already seen that the sinus is closely related to the nose – lying beside and connected to it. Therefore, when the maxillary sinus fills with blood, it can often overflow into the nose and lead to bleeding through the nostril or posterior nose. This can happen with any midface trauma. To stop the bleeding, in the first instance, we can pack the nose (anteriorly and posteriorly).

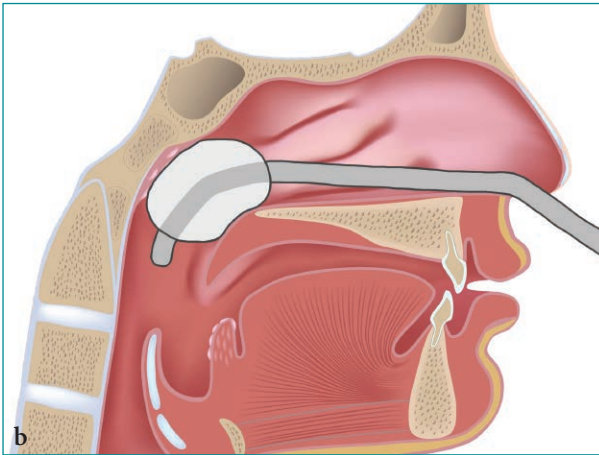


*Figure 3.6: Procedure for anterior nasal packing using a Merocel® nasal tampon. (a) Insertion of the tampon (note the angle of insertion) and (b) the tampon expanded within the nasal cavity.*



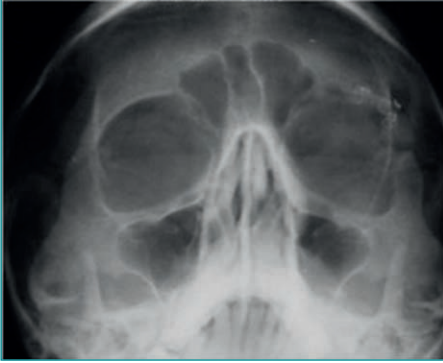


*Figure 3.7: Procedure for posterior nasal packing using a Foley catheter. (a) Insertion of the catheter (note the angle of insertion) and (b) the catheter balloon expanded within the posterior nasal space.*



Figures 3.6 and 3.7 show the method of both anterior and posterior nasal packing. The aim is to stop the bleeding by pressure or tamponade. However, this sometimes doesn't control the bleeding from a midface fracture because the edges of the fractured bones themselves continue to bleed. The way to stop this bleeding is to compress the bone edges, which we do with a bite block. Of course, once the acute bleeding has settled, these injuries may well require operative fixation under GA, where we can ensure the fractures are reduced and fixed in the correct place using a combination of miniplates, wires and braces.

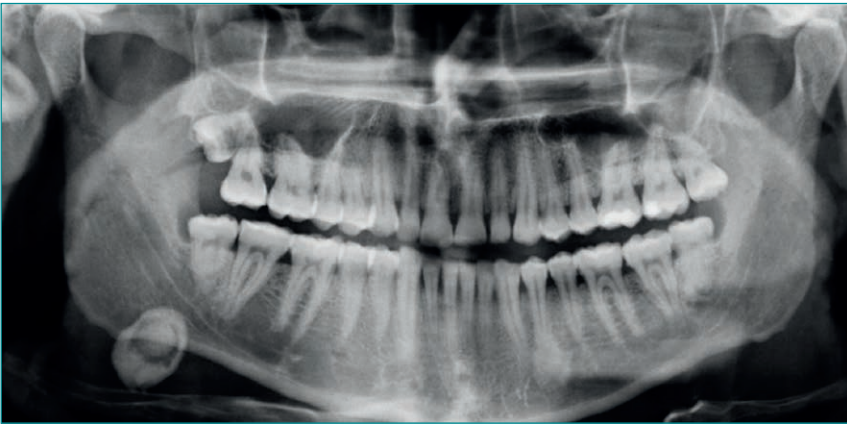Along similar lines, the presence of fluid in the maxillary sinus (particularly in a patient who has suffered an injury to the face) can also help support a diagnosis of a facial bone fracture. Noting the presence of fluid in the sinus has become an important part of analysing a facial bones radiograph.



*Figure 3.8: This is an occipitomental or 'facial view' radiograph. As you can see, this patient is actually post-surgery, having had their left supra-orbital rim fracture repaired with wiring. This x-ray shows that normally the maxillary sinuses are black. When looking for fractures of the midface, the sinuses can often fill with blood or herniated orbital contents. This would appear on an x-ray as grey contents within the sinus. Picture courtesy of Mr. G. Bounds*

### 3.5 DENTAL PATHOLOGY

Aside from being intimately related to the orbit above and the lateral nose to the side, the maxillary sinus is also closely related to the upper teeth below it – and in particular to the premolar and large molar teeth on either side.



*Figure 3.9: Whilst this OPG demonstrates a right submandibular stone, it also shows the close proximity of the upper teeth to the maxillary sinuses. It is not uncommon for a root to be pushed into the sinuses when a dentist extracts it, or more commonly, for a hole to remain between the sinus and oral cavity. This is called an 'oroantral communication'. Picture courtesy of Mr. S. Walsh*

This is important for a number of reasons. Problems with these teeth – such as acute or chronic dental infections – can lead to sinusitis-like symptoms; and conversely, sinus inflammation can lead to dental pain. Each can be mistaken for the other!

In addition, there are a number of cyst-like lesions that can arise from or around teeth and extend into the maxillary sinus. The most common cysts tend to arise from teeth that have had chronic infections, but there are many differentials. Occasionally, we might be required to retrieve a tooth root or dental filling material that has become displaced into the sinus! In such cases, we may need to make a small cut in the mucosa of the upper gums, find the anterior wall of the sinus and make a small window in the maxillary bone to access whatever is inside.

On other occasions, we might need to place things into the sinus. Dental implants are becoming increasingly popular. They are made predominantly of titanium, but treated in such a way that they osseointegrate with the bones of the jaw. This keeps them stable, prevents infection and allows them to withstand the forces that arise within the jaw. However, on occasion there is not enough bone for these implants to be placed, and in such cases, we are often asked to place bone grafts into the bottom of the sinus. Once healed and established, this additional bone height allows implants to be placed and to osseointegrate. Sometimes, implants can even be placed into the bone of the zygoma, but such cases are usually reserved for situations when the amount of bone has been significantly reduced – for example, after a cancer resection.

### **3.6 SKIN CANCERS ON THE NOSE AND CHEEK**

Any skin cancers are managed in conjunction with dermatologists and oncologists as part of a skin cancer multidisciplinary team (MDT). The central face is a high-risk site for the development of skin cancers such as basal cell carcinomas and squamous cell carcinomas. These cancers often require surgical excision. This can be done via Mohs micrographic surgery, where lesions are excised and microscopically assessed there and then to confirm the tumours have been removed in their entirety. They can also be excised by a wide local excision, where the cancers are removed with a 4–6mm cuff of normal-looking skin tissue around the tumour. Although these numbers sound small, they lead to considerable defects in aesthetically sensitive areas, as mentioned in an earlier chapter for the scalp and forehead. Coupled with the complex 3D shape of the nose, and to a lesser extent the cheek, reconstructing these defects once the cancers have been removed can be challenging – but also immensely satisfying.

Sometimes we can close these defects primarily. Sometimes we allow wounds to heal via secondary intention. Sometimes we use a scaffolding material to aid this process. Often, we prefer to use local skin flaps to help close these areas. Here, we use our knowledge of the relaxed skin tension lines to shift skin from areas that have more laxity to areas that have less movement, to allow us to close defects that we would otherwise not be able to.

Sometimes parts of the cartilaginous framework (alar cartilages) that support the nostrils also need to be removed. To reconstruct this area, we often use a conchal cartilage from the bowl of the ear to replace the alar cartilage, which gives the nostril its shape. Occasionally, for large defects, we need to perform a forehead flap, taking a flap of skin from the forehead, and turning it around to rebuild the nose. After a few weeks, when it has gained a blood supply from the nasal area, the flap pedicle can be divided from the forehead region.

### 3.7 CLOSING COMMENTS

The midfacial third is a complex region involving the nose and upper jaw, along with the complex structure housed within the bones and the soft tissue superficial to them. This chapter has walked you through some of the important problems that patients present with in these regions, and introduced the principles that surgeons use to manage them. In the next chapter we will focus more closely on the jaws themselves, which requires a detailed look inside the oral cavity.



*A woman with bilateral temporomandibular joint ankylosis; failed development and fusion of the jaw joints with stunted mandibular growth following severe ear infections in childhood.*

# CHAPTER 4: THE JAWS

## 4.1 ANATOMY AND EMBRYOLOGY

By the fifth week of intra-uterine development, the face consists of five facial prominences:

- Fronto-nasal prominence
- Paired maxillary prominences
- Paired mandibular prominences.

Between weeks five and eight of intra-uterine development, a number of these processes fuse. Aberrations in this process can result in various clefts including a laterally deflected nose, cleft lip and/or palate.

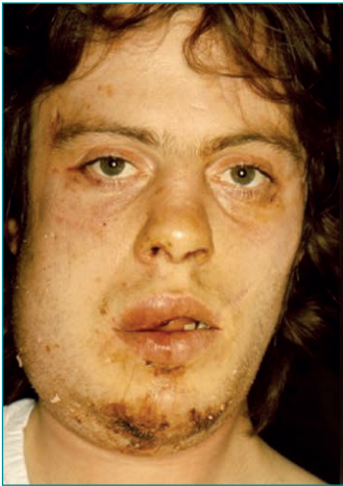Together, the mandible and maxilla form the framework of the oral cavity, thereby playing a crucial role in mastication, swallowing and speech. It would be a good starting point before reading this chapter to remind yourself of the bony anatomy of the maxilla and mandible (including the inferior alveolar nerve passing into the mandible at the mandibular foramen and exiting at the mental foramen, where it provides sensation to the lower lip and chin), the temporomandibular joint (TMJ) (including the condyle, disc and glenoid fossa in the temporal bone) and the muscles of mastication (including masseter, temporalis, medial pterygoid and lateral pterygoid). These muscles of mastication are innervated by the trigeminal nerve. In contrast, the facial expression muscles are innervated by the facial nerve.

## 4.2 FRACTURES OF THE MANDIBLE AND MIDFACE

### 4.2.1 MANDIBULAR FRACTURES

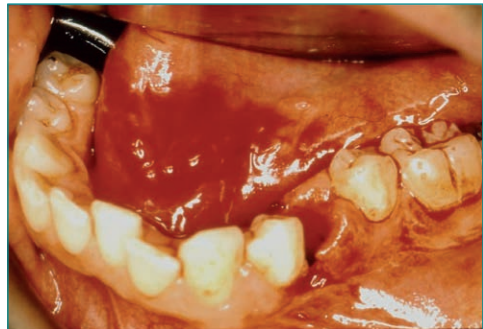Facial trauma is very common and, given its location, the mandible often bears the brunt of such force. As oral and maxillofacial surgeons, we see a myriad of facial trauma but will always have a high suspicion for mandibular trauma. As with all fractures, a focused history and examination are crucial and further investigations, such as imaging, should seek to confirm the precise location and orientation of any fracture and assess displacement of the bony fragments. A mandible fracture may present in a clinically obvious way but sometimes the signs are more subtle, especially with non-displaced fractures.

On examination, you might see a clearly visible deformity of the jaw; pain and swelling around the jaw; teeth that are out of line and don't meet correctly (altered occlusion); a gingival tear and bleeding within the oral cavity; and possibly numbness (paraesthesia, i.e. changed or altered sensation) of the lip and chin due to trauma to the inferior alveolar nerve.



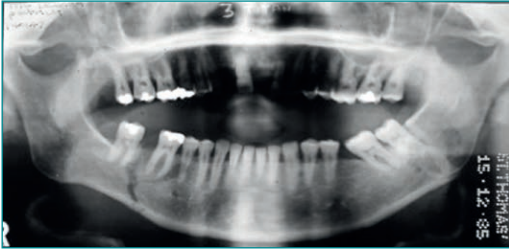
*Figure 4.1: This gentleman has been assaulted. He has a right-sided facial swelling and reports a change in feeling to his lower lip. Picture courtesy of Mr. G. Bounds*

*Figure 4.2: Intra-oral examination of a potential fractured mandible can show gingival tears, movement of teeth from their sockets, bleeding and haematoma formation. Picture courtesy of Mr. G. Bounds*

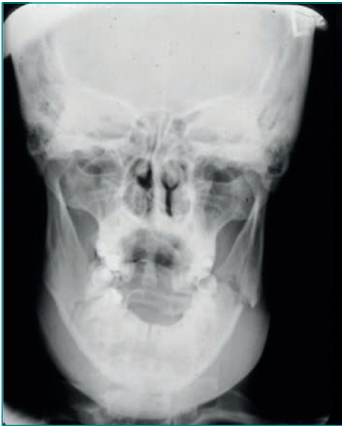



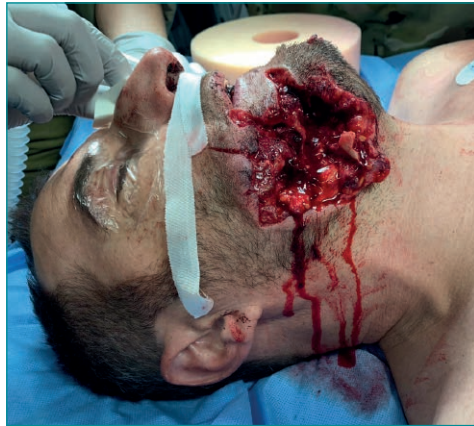Any of the above should prompt plain film radiography in the first instance, or if part of a major trauma ('polytrauma'), a head-to-toe CT scan. For mandible fractures alone, an orthopantomogram (OPG) in combination with a PA (postero-anterior) mandible plain film is all that's needed. In essence, the OPG 'flattens' out the jaw from a U-shape to provide a 2D image and the PA mandible provides a back-to-front look at the mandible, particularly useful for assessing fracture displacement.



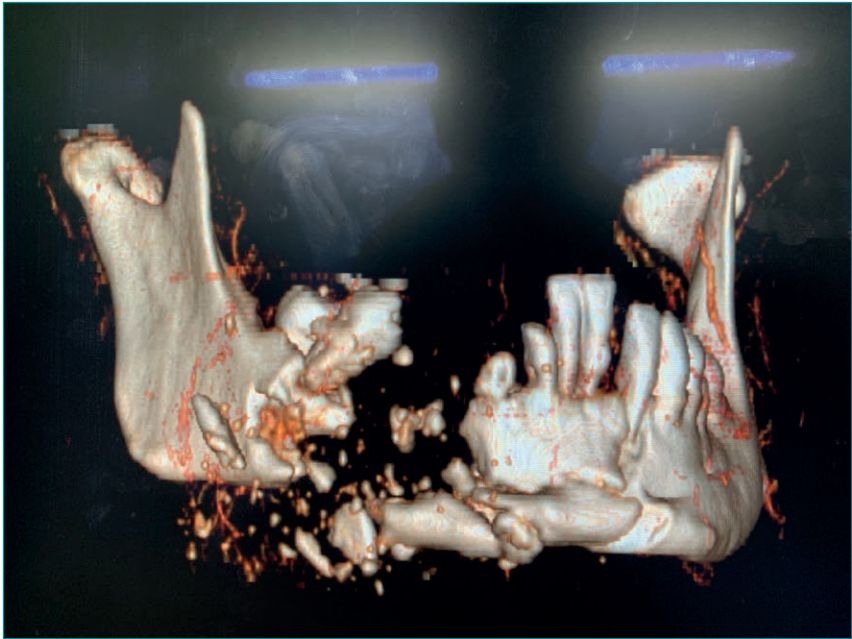
*Figure 4.3: This is an OPG. Notice how it flattens out the jaw and is useful for assessment of the TMJ, dental pathology and also fractures. Here, a fracture of the right body and left angle can be seen. Picture courtesy of Mr. G. Bounds*



*Figure 4.4: This PA (postero-anterior) mandible plain film provides a back-to-front look at the mandible. This, together with an OPG, is the first-line investigation for a fractured mandible. Picture courtesy of Mr. G. Bounds*



*Figure 4.5: This gentleman presented with significant facial trauma secondary to a gunshot wound. On arrival at the emergency department he would have been managed as per ATLS principles. Picture courtesy of Lieutenant Colonel Johno Breeze*



*Figure 4.6: A 3D reformatted CT scan identified a grossly comminuted right body of mandible fracture, with likely loss of tissue and teeth. Picture courtesy of Lieutenant Colonel Johno Breeze*

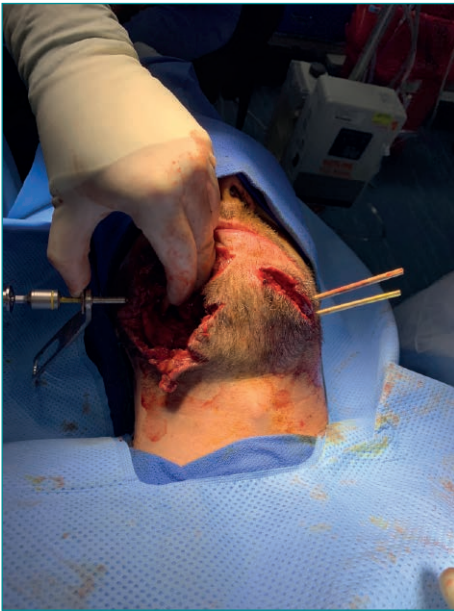## Management

To consider the management and surgical treatment of mandibular fractures, one must first recap the bony anatomy of the mandible and the separate regions we define. The mandible is described as having a condyle, coronoid process, ascending ramus, angle, body, parasymphysis and symphysis. As the mandible is a 'U' shape, trauma to one side of the jaw will often cause contralateral injury (i.e. a double fracture). Furthermore, patterns of injury emerge that are very common – for example, an angle fracture with a contralateral condyle fracture. You may hear fractures described as 'favourable' or 'unfavourable'; simply put, this is describing the orientation of the fracture in relation to the pull of the surrounding musculature. A fracture that is supported and held in place by the pull of a group of muscles is less likely to be displaced and may lend itself to more conservative (i.e. non-operative) treatment.

When we talk about surgical management of a mandible fracture, we are asking the question 'do we need to stabilise the jaw or will the fracture heal on its own?' If the fracture is non-displaced and favourable with a co-operative

patient then it's reasonable to trial a period of conservative treatment and review the patient after one week.

On the other hand, if the fracture is going to move then the bone won't heal, so we then need to reduce and stabilise the bony fragments. We can do this via a closed reduction, where we don't open up and expose the fracture, but we use the teeth or bone to guide the fracture into place with brackets and wires around the teeth. Alternatively, we may need to surgically open the fracture site, reduce the bony fragments and fix them in the correct anatomical position using small but very strong titanium plates and screws. This is called open reduction, internal fixation (ORIF).



*Figure 4.7: The patient required open reduction internal fixation of the mandible. Where possible, we try to do all of this from inside the oral cavity. In some instances, such as this, we have to approach the fracture from an extra-oral route. Picture courtesy of Lieutenant Colonel Johnno Breeze*

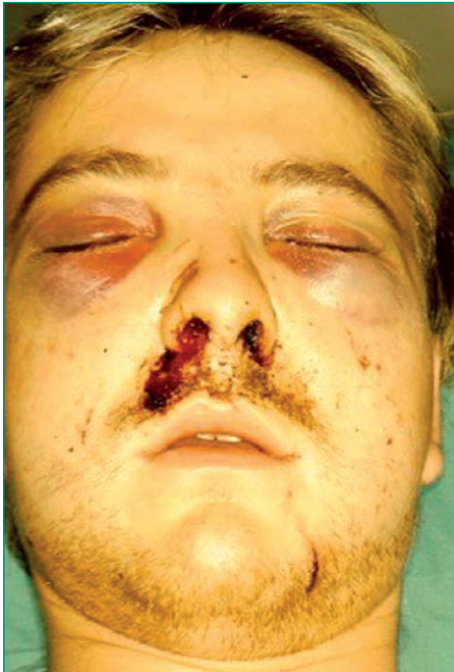The above principles are applied in general to most mandible fractures, with the exception of certain sub-sites, such as the mandibular condyle, which have their own specific treatment and more complex management algorithms.

## 4.2.2 MIDFACE FRACTURES

The midface is a complex structure derived from the union of a number of bones. The largest bone of the midface is the maxilla, which provides support to the tooth-bearing structures, sinuses, globes and muscles of facial expression.

### 1. Maxillary fractures

Because, as discussed above, the maxilla has several anatomical functions, the presentation of these fractures can be varied – from no clinical signs but with a subtle fracture on imaging, to gross comminution ('smashing' into multiple pieces) and displacement. Such signs include: movement of teeth and an altered bite; mobility of the bone; potential for significant bleeding; and involvement of the orbits and zygomatic bone (discussed below).



*Figure 4.8: A patient with a fractured maxilla can often present with epistaxis, an elongated face and an anterior open bite. This is where they are biting on their back teeth, but their front teeth are wide apart. This is because the maxilla is pushed backwards, 'jacking open' their occlusion. Picture courtesy of Mr. G. Bounds*

### Classification

Midface fractures are commonly classified according to Le Fort patterns. This eponymous classification is named after Rene Le Fort, a French surgeon who spent his spare time hitting cadaveric skulls with clubs and iron rods(!), identifying some key fracture patterns. The midface fractures occurred in some specific patterns because of facial buttresses (three horizontal and three vertical) that dictated the distribution of forces through the bone. These buttresses are strong and denser vertical and horizontal columns of bone that provide form and functional strength to the midface.

Le Fort I	A horizontal fracture separating the palate and the tooth bearing maxilla from the alveolus. Extends through the floor of the nose.
Le Fort II	A 'pyramidal' fracture extending from the frontonasal suture through the medial wall of the orbit to the zygomatico-maxillary suture.
Le Fort III	Complete craniofacial dysjunction From nasofrontal suture, through both medial and lateral walls of the orbit extending to the zygomatico-frontal suture.

*Table: The Le Fort classification*

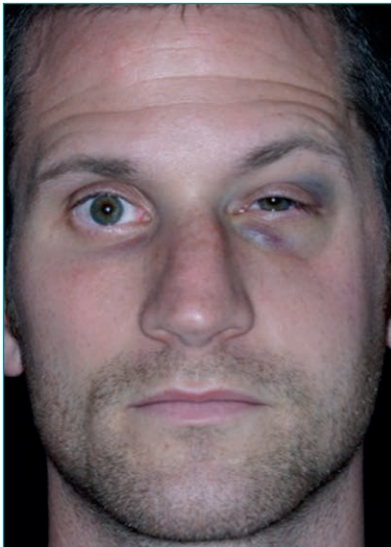## Management

It is commonly accepted that Le Fort fractures should be operated on within 10–14 days of injury, after initial swelling has reduced (or very soon after the injury, before any significant swelling occurs), as soft-tissue swelling can make anatomical repositioning of fracture segments more difficult. Depending on the type of fracture, we can access these in the form of intra-oral incisions, lower eyelid incisions or via a scalp-based coronal flap. Surgery will take the form of ORIF, titanium miniplates and screws. The primary aim of midfacial surgery will be to restore the continuity of bone by strengthening the aforementioned facial buttresses.

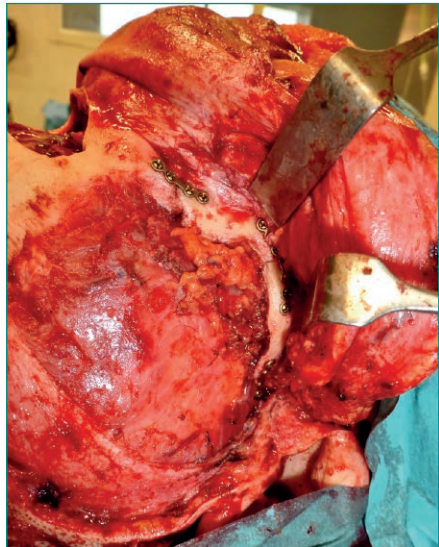
### 2. Zygomatic fractures

The zygomatic bone, or zygoma, provides width and profile to the face. It articulates with the frontal bone above, the maxilla below and, via its 'arch', with the temporal bone. It also forms a significant portion of the lateral wall of the orbit.

As expected, injuries to the zygoma are not uncommon, due to its prominent position on the lateral face. In general, we group zygomatic fractures into more simple zygomatic-arch fractures and ‘tripod’ (better described as ‘quadripod’) fractures, whereby the zygoma fractures in three positions of union with nearby facial bones and the entire body of the zygoma (or zygomatic complex) is displaced. The term ‘tripod’ is something of a misnomer because there are actually four key points of fracture (lateral orbit, zygomaticomaxillary buttress, arch of zygoma and the orbital floor). As discussed in Chapter 2, the orbital floor component can cause numerous eye signs and symptoms.



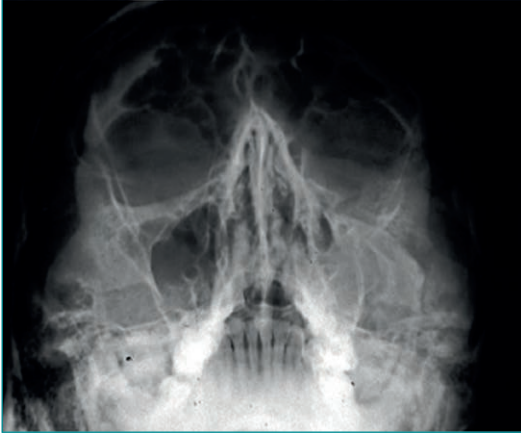
*Figure 4.9: The zygoma provides width to the face. Here you can see the flattening of the left cheekbone or zygoma. This can also cause peri-orbital ecchymosis, subconjunctival haemorrhage and infra-orbital sensory loss. Picture courtesy of Mr. G. Bounds*



*Figure 4.10: Here you can see the zygoma has fractured at the lateral orbital wall, called the zygomatico-frontal suture, and on the arch itself. It has been fixed with miniplates and screws via a coronal approach. This is not always required, as we can usually approach the zygoma with inconspicuous incisions. Picture courtesy of Mr. M. Ethunandan*

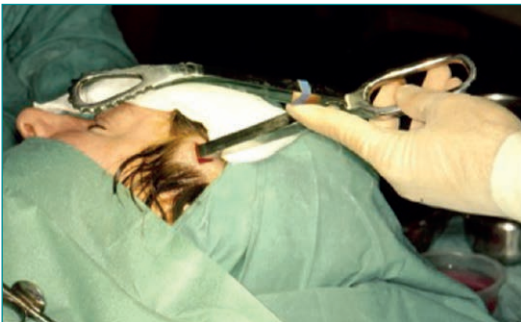When you examine a patient with a zygomatic fracture, you might see a visible flattening of the cheekbone; numbness of the cheek due to infra-orbital nerve involvement; decreased mouth opening, if a fractured zygomatic arch is trapping the coronoid process of the mandible (where the temporalis muscle

attaches); and/or orbital involvement. Eye symptoms may include swelling, subconjunctival haemorrhage, double vision (diplopia) and reduced eye movement (particularly in the upward gaze).



*Figure 4.11: This occipitomental radiograph indicated a left zygoma fracture. Again, when assessing such x-rays, it is useful to look for symmetry, or in this case asymmetry. Picture courtesy of Mr. G. Bounds*

Surgery is performed when there is an aesthetic or functional deformity. Again, we normally wait 10–14 days to allow the swelling to settle and for additional injuries such as orbital floor/wall defects to manifest and be assessed accordingly.



*Figure 4.12: As we have highlighted throughout this book, oral and maxillofacial surgeons attempt to minimise facial deformity as best as possible. Here the zygoma is lifted into the correct position through an incision placed in the hair to hide the incision. Picture courtesy of Mr. G. Bounds*

## 4.3 JAW DEFORMITY

### Orthognathic surgery

Orthognathic surgery is a sub-specialty interest area of OMFS concerned with facial deformity as a consequence of abnormal skeletal, soft-tissue and dental relationships in horizontal, transverse and vertical planes. More recently, orthognathic surgery is also being performed as a highly effective treatment for obstructive sleep apnoea, as forward movement of the jaws can improve airflow through the nasopharynx and oropharynx.

Some facial deformities are associated with syndromic conditions, sometimes with an underlying genetic aetiology. However, more often the deformity will be multifactorial, due to an abnormality of skeletal bone growth, functional muscle attachments and environmental influences.

When we assess a patient with a facial skeletal deformity who warrants treatment, we are primarily concerned with improving their function. This may help with the patient's bite and chewing, or even speech and swallowing. Improving function is achieved via restoring the 'normal' form and relationship of the facial skeleton and soft tissues.

#### 4.3.1 ASSESSMENT

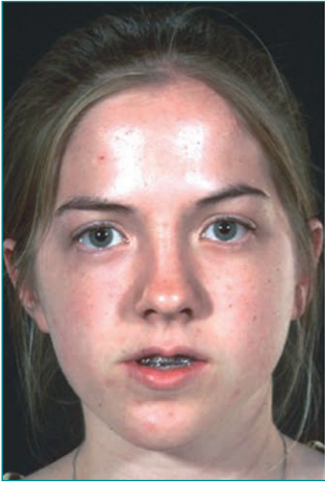A thorough history and clinical assessment are performed for all facial deformity patients. This must include existing function, any TMJ complaints and a detailed discussion of the patient's ideas and expectations. More often than not, a pre-designed proforma will be used to ensure all facial measurements are recorded accurately. It is outside the scope of this book to detail the terminology and examination of a facial deformity patient. However, this allows for an extensive assessment of the patient against 'normal' parameters, from which a treatment plan can be created in conjunction with an orthodontist (dental specialist) and OMFS laboratory staff.

#### 4.3.2 EXAMINATION

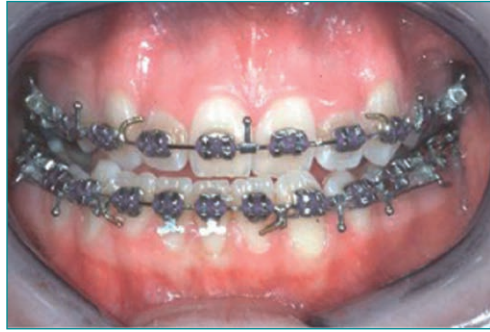When faced with a complex deformity case, this is often quite challenging. You should now be aware that we divide the face into 'thirds' and most often we are concerned with the 'middle third' (i.e. the maxilla) and the 'lower third' (i.e. the mandible) when considering or performing surgery to these bones. It might sound simple, but the goal of the examination is to determine the specific facial component (bone, soft tissue or both) contributing to



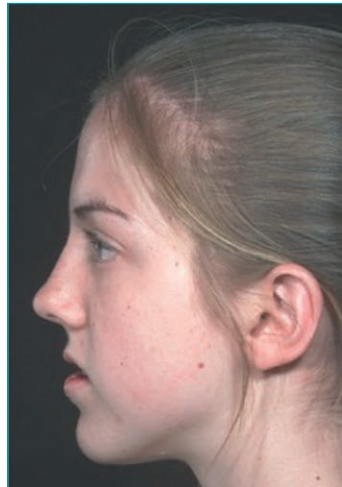the deformity – i.e. is the middle third overdeveloped or is the lower third underdeveloped? and vice versa. A key component of our decision is the relationship of the top and bottom teeth. We describe this according to how the incisors (front teeth) meet. A Class I relationship is considered normal and the top incisors are 2–4mm in front of the bottom incisors; in a Class II relationship, the top incisors are greater than 4mm in front; and in a Class III relationship, the lower jaw protrudes and the lower incisors are in front of the upper incisors.



*Figure 4.13: Looking at this young lady from 'front on', it looks very much like her chin is pointing more to the right. Picture courtesy of Mr. A. Sidebottom*



*Figure 4.14: As you can see, her top-teeth (jaw) midline is not coincident with the lower-teeth (jaw) midline. Picture courtesy of Mr. A. Sidebottom*



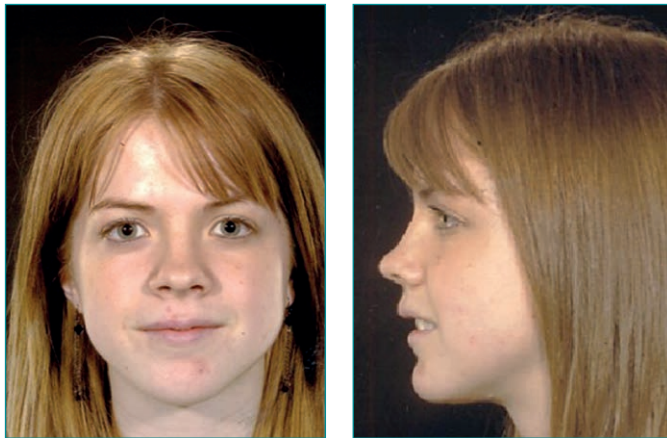*Figure 4.15: From the side, it looks like the lower jaw is slightly in front of the upper jaw. This would be considered a Class III skeletal pattern or jaw relationship. Picture courtesy of Mr. A. Sidebottom*

### 4.3.3 TREATMENT

Treatment for facial deformity is an entire treatment pathway and not one discreet surgical procedure. At the initial assessment, we will use photographs, impressions of the teeth and radiographs to detail the patient's baseline skeletal jaw and facial soft-tissue relationship. Treatment commences with orthodontics (braces) for several months, in preparation for surgery with or without secondary surgery, followed by post-surgical orthodontics – all taking up to two years or more.

### Surgical treatment for facial deformity

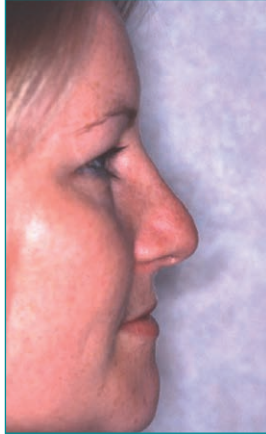
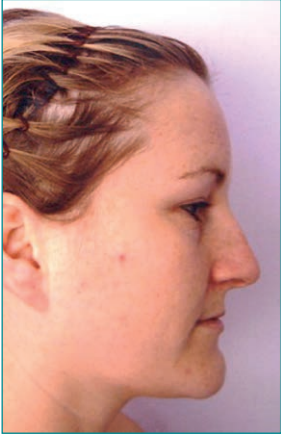Having considered the above, the goal of surgery is to break the jaw bones (known as 'osteotomy') in a controlled and careful way, and then to move them into a more normal and functionally favourable position. Having done this, we then fix them with titanium plates and screws – the same ones we use for facial trauma, as mentioned before. There are countless approaches, methods, surgical techniques and fixation devices used to achieve this goal. Commonly, surgery to the mandible is termed a 'bilateral sagittal split osteotomy' (so-called because of the orientation of the cut through the ramus of the mandible) and to the maxilla a 'Le Fort osteotomy' (similar to the fracture pattern described earlier). These procedures are either performed in isolation or together to achieve a greater degree of dental and bony movement. When performed together, the procedure is termed a 'bimaxillary osteotomy' – a historical term from when the jaws were termed the upper and lower maxillae.



*Figures 4.16 & 4.17: The young lady from Figs. 4.13–4.15 underwent a condylar shave to treat condylar hyperplasia and a bimaxillary osteotomy to move both jaws. As you can see, her chin is now in the midline and her lower jaw is behind her upper jaw. Pictures courtesy of Mr. A. Sidebottom*

## Additional procedures

Additional surgery may include genioplasty, to reshape the chin, or palatal expansion surgery to widen the upper jaw. Furthermore, movement of the jaws can affect the appearance of the nose and sometimes even a second-stage rhinoplasty is performed.



*Figures 4.18 & 4.19:  
This lady underwent a  
reduction genioplasty  
and rhinoplasty. Note  
that you can see that  
her chin is more level  
with her upper jaw.  
Pictures courtesy of Mr.  
A. Sidebottom*

An alternative to moving bones and fixing them during one procedure is distraction osteogenesis. Here, we break the bones and insert a distracting device to slowly (millimetres per week) pull them apart, and wait for the new bone to form as we distract. Such an approach is useful in paediatric syndromic patients with gross deformities not amenable to a single-stage procedure.

## 4.4 THE TEMPOROMANDIBULAR JOINT (TMJ)

### 4.4.1 ANATOMY

The TMJ is a complex region of the facial skeleton. It is comprised of the condylar head of the mandible, the glenoid fossa at the base of the skull, a cartilaginous intra-articular disc separating an upper and lower compartment, each filled with synovial fluid, surrounded by an overlying joint capsule and influenced by muscles of mastication. Pain and dysfunction of the TMJ is now thought to be a multifactorial problem, sometimes with a strong contributing psychological component. It can sometimes be associated with irritable bowel syndrome (IBS) or other similar conditions.

### 4.4.2 EXAMINING THE TMJ

When examining the TMJ, we are assessing the gross function of the joint to open and close the mouth, and then also signs on the teeth that may be causing or exacerbating a TMJ problem. We will ask the patient to open and close their mouth, looking for equal movement and adequate mouth opening, then examine the teeth, palpate the TMJ for pain and crepitus, and palpate the muscles of mastication (masseter, temporalis, lateral and medial pterygoids). For example, a patient who grinds their teeth, causing trauma to the TMJ as a result, may have signs of tooth wear and masseteric hypertrophy. A baseline OPG radiograph will screen for any obvious TMJ bony abnormality, although sometimes MRI may be required, depending on the severity and nature of the TMJ dysfunction.

### 4.4.3 TEMPOROMANDIBULAR JOINT DYSFUNCTION (TMJD)

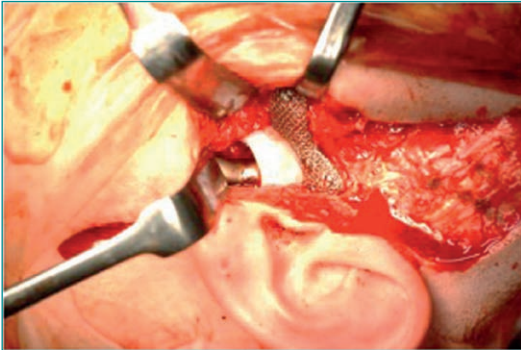
Although TMJD has been through several incarnations of terminology and classifications, in essence it describes a condition with one or several symptoms of jaw dysfunction – specifically pain, trismus (reduced mouth opening), restricted lateral mandibular movement, joint locking, and crepitus (or ‘clicking’). It is a common condition and affects up to 50% of the population at some point in their lifetime. We often see students who present to us with this problem, and it can be associated with stress or even pending exams. As alluded to, such cases are often complex and multifactorial in nature. Whilst the distinction is not always clear, for treatment purposes it is useful to think of TMJD as being articular (to do with the joint itself) or non-articular.

## Management

The treatment of TMJD is tailored to the underlying cause. Pain and dysfunction originating from a non-articular cause are often myofascial (soft tissue) in origin and rarely require surgical intervention. Adjuncts such as a bite guard may help night-time grinding, and local measures can ease muscular pain (such as a hot compress, NSAIDS, jaw physiotherapy and a softer diet). Pain that is chronic in nature may benefit from tricyclic antidepressant medication such as nortriptyline or amitriptyline.

Articular disease is associated with an abnormality of the joint itself. Whilst the majority of cases are idiopathic, history of prior mandibular trauma, septic arthritis, osteoarthritis or rheumatoid arthritis can point towards a definitive organic diagnosis.

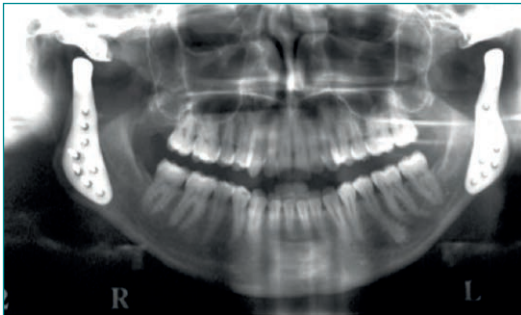
Options for surgical intervention include arthrocentesis (joint washout to reduce inflammation), arthroscopy (to wash out and inspect the joint, and sometimes minimally operate on the joint) and open joint surgery. A degenerative condition of the TMJ that is refractory to conservative treatment may eventually require a joint replacement. In this instance, the joint is exposed surgically and a joint prosthesis implanted to restore function, either with unilateral or bilateral surgery. This surgery is technically challenging – and the facial nerve is intimately related to the TMJ, too!



*Figure 4.20: This is an intra-operative picture of a TMJ replacement. An incision is hidden in a crease in front of the ear. Great care is taken to find access to the joint without compromising the facial nerve or its branches. Picture courtesy of Mr. A. Sidebottom*

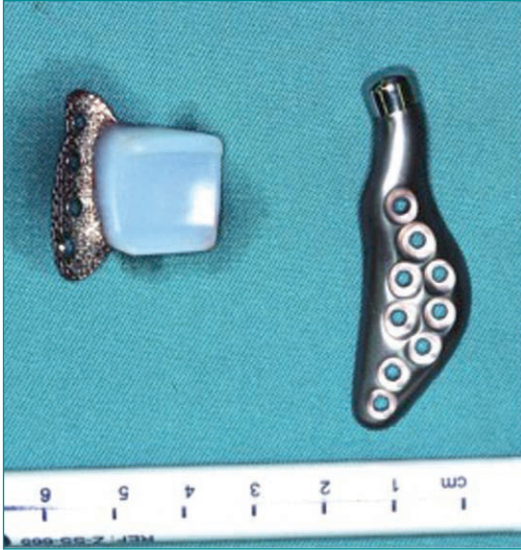

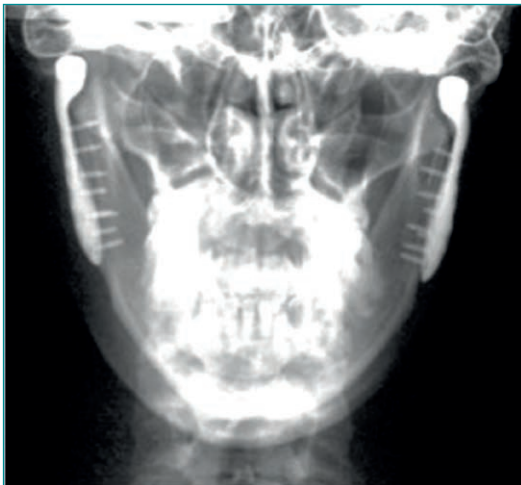Figure 4.21: This is a prosthetic mandibular condyle (right side of picture) and glenoid fossa (left side of picture). Picture courtesy of Mr. A. Sidebottom



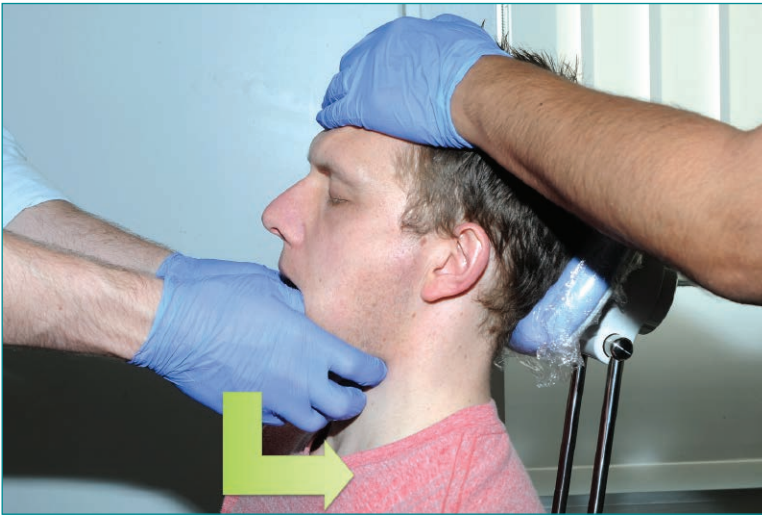
Figures 4.22 & 4.23: Postoperative OPG and PA mandible showing new bilateral temporomandibular joints. Note the condylar prosthesis is fixed to the ascending ramus of the mandible. Pictures courtesy of Mr. A. Sidebottom



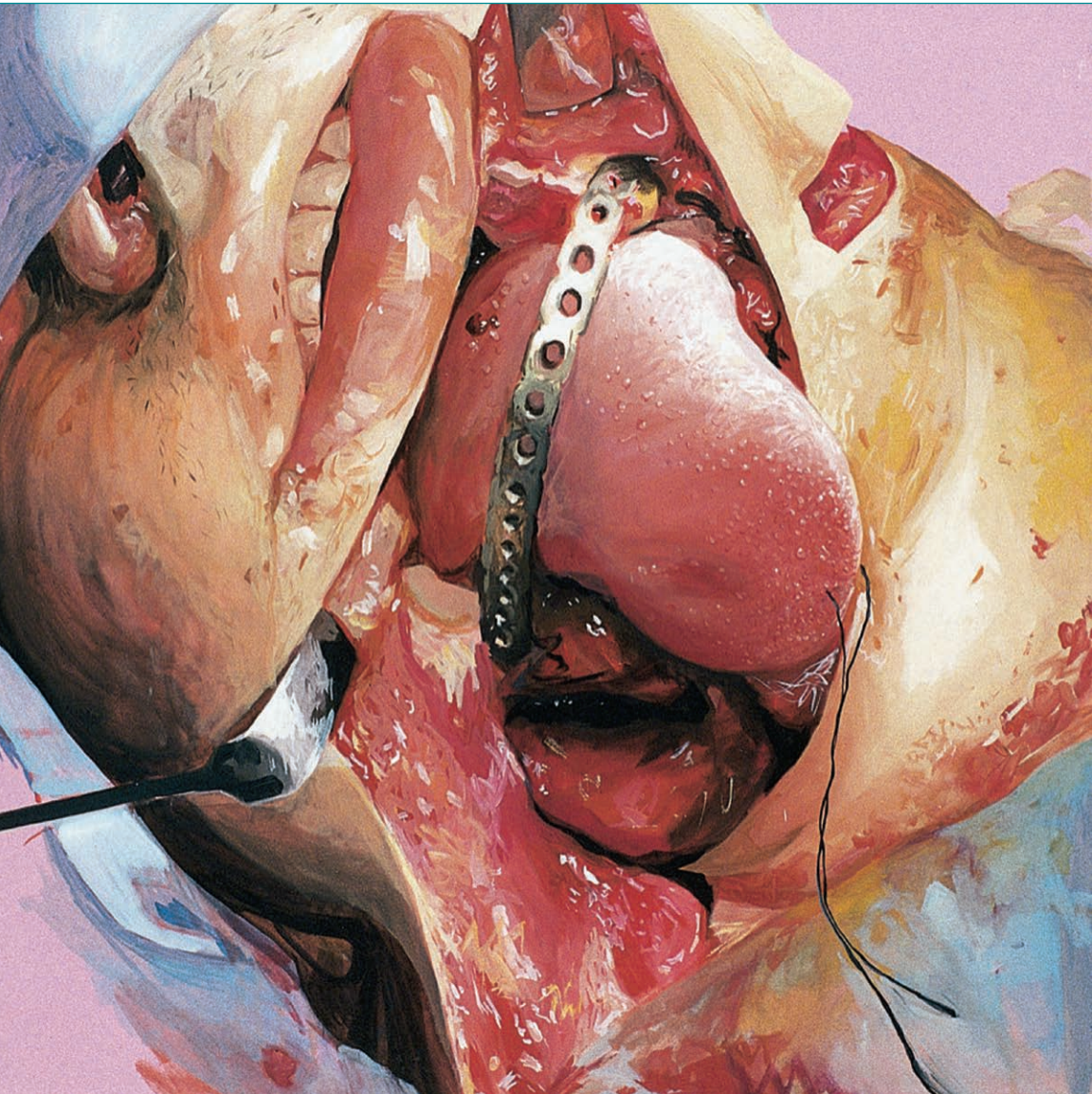
#### 4.4.4 TMJ DISLOCATION

Patients who present with a sudden-onset inability to close their jaw with their mouth in a wide-open position will most likely be suffering with a dislocated TMJ. Here, the condylar head has slipped forward over the articular eminence. There may be a prior history of TMJD or excessive mouth opening such as yawning or undergoing prolonged dental treatment. Patients are often distressed and report previous similar episodes.

The earlier the jaw is relocated, generally the easier the procedure is to carry out. As soon as feasibly possible, one should attempt to relocate the jaw by applying sustained bilateral thumb pressure inside the mouth on the retromolar pads in order to manipulate the condyle under, and posterior to, the articular eminence of the temporal bone. The fingers are placed around the outside of the jaw to help stabilise the jaw. With time, this can be challenging due to masticatory muscle spasm (which may require intravenous sedation or even a GA with muscle relaxant to achieve joint reduction).



*Figure 4.24: Reducing a dislocated mandible. Note support of patients head and position of hands around mandible.*

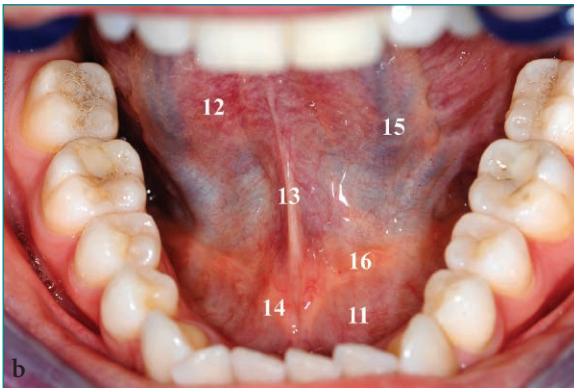
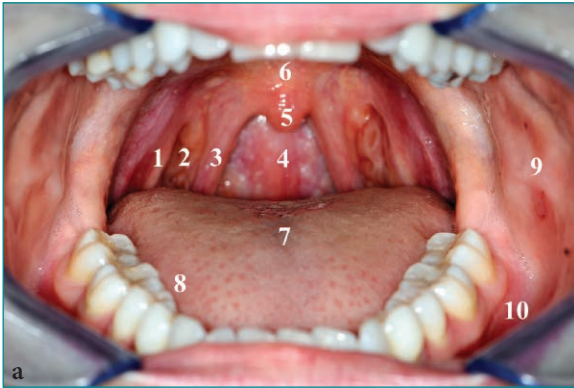


*Resection of the anterior mandible and lower lip for cancer, with a titanium plate in position prior to inseting of a scapula bone free flap into the jaw defect.*



# CHAPTER 5: THE MOUTH

## 5.1 ANATOMY



*Figures 5.1a & 5.1b: Intraoral and b) floor of mouth anatomy. The Parotid duct drains via the Parotid papilla, which is out of sight, opposite the upper second molar teeth bilaterally:*

- |                              |                                 |
|------------------------------|---------------------------------|
| 1. Palatoglossal arch        | 9. Buccal mucosa                |
| 2. Palatine tonsil           | 10. Buccal sulcus               |
| 3. Palatopharyngeal arch     | 11. Floor of mouth              |
| 4. Posterior pharyngeal wall | 12. Ventral surface of tongue   |
| 5. Uvula                     | 13. Lingual fraenum             |
| 6. Soft palate               | 14. Submandibular duct openings |
| 7. Dorsum of tongue          | 15. Lingual vein                |
| 8. Lateral border of tongue  | 16. Sublingual fold             |

## 5.2 ULCERS AND PATCHES IN THE MOUTH

Wherever it is on the body, an ulcer is simply a break in the continuity of the epithelial surface due to progressive tissue destruction. In the mouth, it is important not only to clinically examine an ulcer's appearance and site, but also the history of its occurrence. Relapsing–remitting or recurrent ulcers are often caused by different (typically inflammatory) disorders than persistent ulcers (those which appear and never go away are far more likely to be malignant).

### FACT BOX

**When investigating the cause of an ulcer, one must consider the following factors:**

- Risk-factor assessment:
  - Smoker?
  - Drinker?
- Painful vs. painless
- Duration (< or >3 weeks?)
- Persistent vs. recurrent
- Solitary or multiple
- Previous history of oral cancer
- Medication associated?
  - Nicorandil
  - Aspirin
- Associations with other systemic symptoms:
  - Ulcers in other areas (e.g. skin, genital, corneal)
  - History of autoimmune disease

**SINISTER FEATURES:**

- Extending beyond mucosa
- Irregular border
- Firm/indurated
- Associated neck lymphadenopathy – single or more than one node
- Nerve weakness/altered sensation
- Not healed after less than three weeks
- On high-risk areas (lateral tongue, floor of mouth, retromolar, etc.)
- Painless ulcer
- Loose/missing/deviated teeth
- Previous oral cancer history
- Risk-factor history (smoking, ETOH, betel-nut chewing)

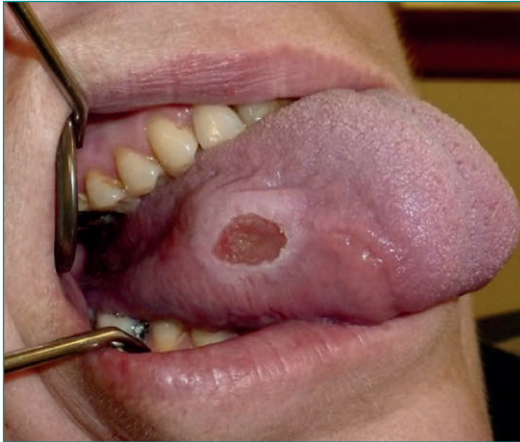**5.2.1 SUSPICIOUS ULCERS**

Oral cancers, most usually squamous cell carcinomas (SCC), often present as a persistent, destructive yet relatively painless, firm and indurated ulcer (present for more than three weeks). These ulcers aren't like a normal aphthous ulcer, which are small and painful; they are destructive and will spread beyond the soft mucosal surfaces onto the firmer gingiva and into deeper tissues (sometimes you will see necrotic muscle/fat/bone at the base). As the cancer invades surrounding nerve fibres, a once-painful ulcer may become surprisingly painless. If a cancer invades a named peripheral nerve (such as the inferior alveolar nerve or hypoglossal nerve), problems like lower-lip numbness or asymmetrical tongue protrusion might be seen on examination. Bone tends to be invaded later and may lead to loose teeth or even fracture of the jaw – beware of a patient with unexplainably loose teeth next to a swelling or persistent mouth ulcer! Irregular shape and, most importantly, induration (palpable firmness) should raise suspicion for cancer, as should the presence of firm, palpable lymph nodes in the neck.

**5.2.2 BENIGN MOUTH ULCERATION**

Benign persistent ulceration may be secondary to a persistent insult or irritation to the mucosa. This is commonly seen with chronic local trauma: for example, mucosa rubbing against a sharp tooth or dental filling, or

topical irritants such as daily aspirin use. Furthermore, long-term systemic medications such as nicorandil can produce oral ulceration as a recognised side effect.



*Figure 5.2: This is a traumatic ulcer caused by a sharp tooth. Once the sharp tooth is addressed, the ulcer will disappear. Picture courtesy of Mr. M. Ethunandan*

### 5.2.3 RECURRENT ULCERATION

In the absence of systemic disease, recurrent ulceration – often termed ‘recurrent aphthous stomatitis’ (RAS) – is one of the commonest presentations and has affected up to 50% of the population at some stage or another. They can present during times of stress, including exams. RAS generally presents in three clinical forms: major RAS, minor RAS and herpetiform.

Benign recurrent oral ulceration can also be secondary to systemic autoimmune disease such as pemphigus, pemphigoid and Bechet’s disease – you may come across these in dermatology or autoimmune clinics.

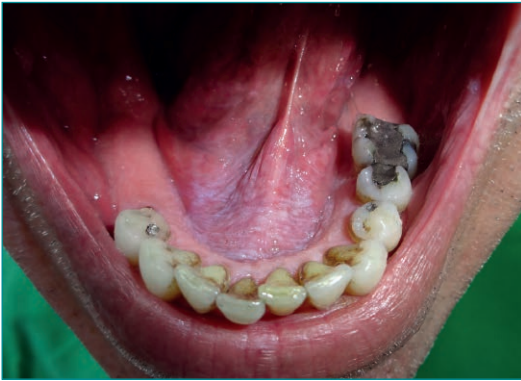Patients with suspected RAS should be investigated for nutritional deficiency (haematinics including iron studies, B vitamins and folate, as well as zinc levels should be evaluated). Psychological stress, as with gastric ulcers, can cause mouth ulcers as well, so these potential causes should be looked into in the first instance. Once these simpler causes are ruled out, a trial of Difflam™ (benzydamine) mouthwash (which has a mild local-anaesthetic action) with or without a steroid mouthwash (e.g. prednisolone or betamethasone) can be initiated. Topical hydrocortisone steroid pellets placed on the ulcer can be very effective as well.

### 5.2.4 PATCHES

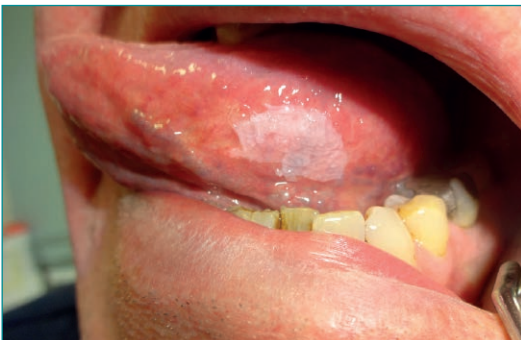Patches are usually white, brown-pigmented, red, or a mixture of colours. Some types are more likely to be premalignant (known as severe dysplasia or carcinoma in situ) or frankly malignant (invasive cancer). They are often flat/macular in nature. Clinical diagnosis can be challenging, based on visual appearance alone. Here, we divide patches into 'mainly red', 'mainly white' or 'pigmented'.

In general, redness indicates a degree of epithelial atrophy or thinning of the mucosa (which may eventually lead to erosion/ulceration). A red patch of unknown origin (erythroplakia) is suspicious for premalignancy/malignant change and warrants urgent investigation.

A white patch that does not rub off gently with a tongue depressor often indicates a 'thickening' of the epithelium, with increased production of keratin. This keratosis may represent premalignant change and there should be a low threshold for subsequent investigation. When there is no identifiable cause, a tenacious white patch in the mouth is called leukoplakia and may well be a premalignant lesion.



*Figure 5.3: This patient presented with a white patch in the floor of the mouth. Incisional biopsy confirmed this was a keratosis. Picture courtesy of Mr. S. Walsh*



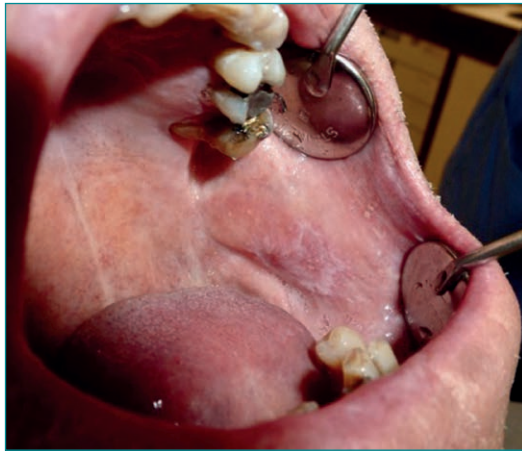*Figure 5.4: This patient presented with a white patch on the left lateral tongue. This would not rub away and there was no identifiable cause. This is therefore called a leukoplakia. A biopsy is the next step in establishing a diagnosis. Picture courtesy of Mr. S. Walsh*

Oral submucous fibrosis (OSMF) is a premalignant condition associated with betel-nut chewing. Betel nut is combined with other agents including tobacco and slaked lime to form gutkha (or paan). This is a habit common, but not exclusive, to South Asian cultures. It presents with a pale, scarred appearance to the buccal (cheek) mucosa, making it rigid and restricting mouth opening.

Pigmented lesions tend to be blue or black in colour. Importantly, whilst incredibly rare, representing less than 1% of head and neck melanoma, mucosal melanoma must be a consideration and should be considered in the differential diagnosis.

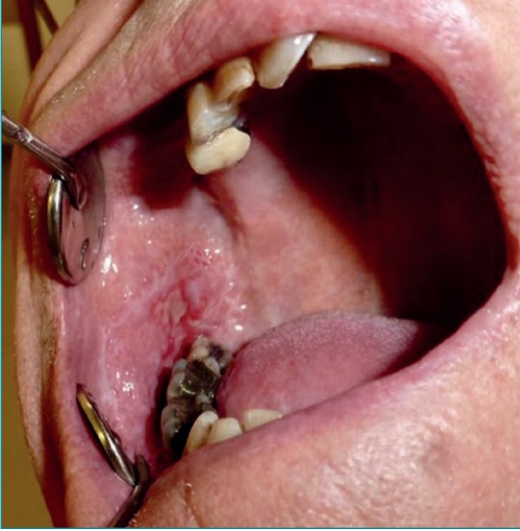### White patches

Oral lichen planus (LP) typically (but not exclusively) presents with symmetrically bilateral lesions on the mucosa/tongue/gingiva. Its appearance can be variable and up to six types have been classified.



*Figure 5.5: This patient presented with lichen planus in the left buccal mucosa. Picture courtesy of Mr. M. Ethunandan*

Patients may present with no symptoms, or experience soreness and discomfort in the area when eating/drinking certain foods (e.g. spicy food). Furthermore, this condition can present with involvement of other epithelial sites (eyes, skin, genital mucosa), which may point to a systemic condition requiring input from other specialties (e.g. gynaecology for vulvovaginal LP). Lichen planus is a T-lymphocyte-mediated disorder and is thought to have malignant potential, so getting the diagnosis by incisional biopsy is important as it may have life-long implications. Treatment varies according to disease severity, from a simple steroid mouthwash and other topical applications, to systemic immunosuppressive medications.



*Figure 5.6: This is a form of lichen planus known as erosive LP. Patients may be asymptomatic or may be in varying levels of pain. Picture courtesy of Mr. M. Ethunandan*

Lichenoid reaction has a similar clinical and identical histopathological appearance to LP (although it is commonly asymmetrically distributed in the mouth) and is secondary to outside causes (drugs, heavy-metal fillings or even a change in toothpaste). The aim of management is to identify and remove the offending cause, as well as relieving symptoms in a similar fashion to LP.

Candidal infection can result in a pseudomembranous coating of the epithelial surface, leaving a white patch. A white patch that easily wipes off with a tongue depressor is highly suggestive of pseudomembranous candidiasis and should respond promptly and completely to antifungal treatments such as fluconazole or topical nystatin. It is often worth asking a patient if they wear their dentures all the time, or if they are using a steroid inhaler. Chronic candidal infection as seen in chronic hyperplastic candidiasis (thickened candida-infected mucosa with a white appearance that doesn't scrape off) does, however, have malignant potential. Patients with this condition need to be monitored and are often treated with regular courses of potent oral antifungal tablets such as fluconazole.

One of the most common benign causes of a white patch in the mouth is frictional keratosis, where a thickening (and therefore whitening) of the epithelium occurs in reaction to chronic mechanical trauma including recurrent cheek biting. This is similar to hard skin on the soles of the feet through heavy walking. If you put your feet into water, this hard skin turns white due to waterlogging. Hard skin in the mouth is constantly bathed by saliva! This diagnosis should only be made if there is an obvious cause. For example, a rough dental filling or a sharp tooth rubbing on the affected area,

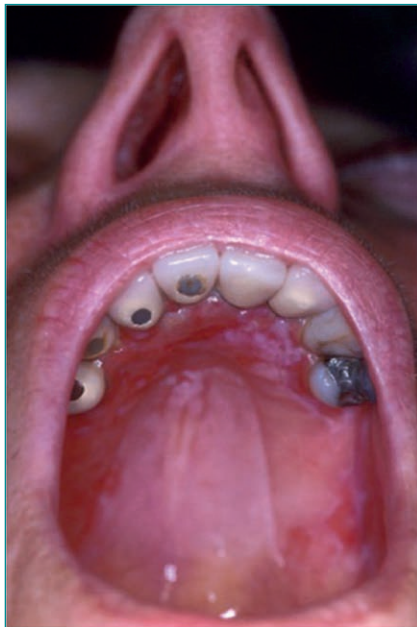or a white thickening of the buccal mucosa in-line with the occlusal plane can cause this frictional keratosis.

White patches can be a completely physiological phenomenon, such as Fordyce spots and leukoedema – a bluish/white hue of the mucosa, more commonly found in people with darker skin pigmentation. This is fine-print stuff for the non-specialist.

### Red patches

Geographic tongue (also known as benign migratory glossitis) has a characteristic 'map-like' morphology, occurring on the dorsum of the tongue. Its cause is unknown. Although it results in alternating areas of sore, red, atrophic mucosa, it is entirely benign and there is no known link with premalignancy or cancer. Diagnosis is made on clinical examination only.

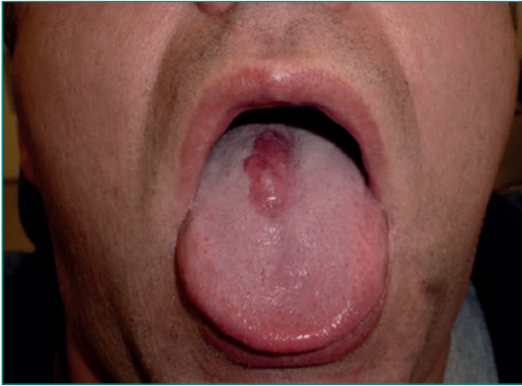Another benign red patch is the red atrophic changes commonly related to an underlying infection such as oral candidiasis particularly seen in denture wearers. This is the result of inadequate hygiene; simple denture care and topical and/or oral antifungals can resolve the situation within days. The clinical picture is of a red patch confined to the mucosa that is in direct contact with the underside of the denture – essentially a size-matched 'print' of the denture fitting surface.



*Figure 5.7: This is a typical presentation oral candidiasis due to inadequate denture hygiene. You can see the erythema fits beautifully within the limits where the partial denture normally sits. You can actually see the outline perfectly! Picture courtesy of Mr. A. Sidebottom*



Angular cheilitis can present as a sore red or cracked area that doesn't heal, most commonly in the corner of the lips. Similarly, candida infection of the tongue can present with a classical midline red patch on the dorsum of the tongue, known as median rhomboid glossitis (MRG). This is treated with a short course of topical and/or systemic antifungal treatment such as fluconazole. However, should atrophic candida infections fail to resolve with appropriate treatment, erythroplakia (and therefore premalignancy) remains a high possibility, warranting urgent investigation.



*Figure 5.8: This is a classic presentation of median rhomboid glossitis. It responds well to antifungal medications. Picture courtesy of Mr. M. Ethunandan*

## Pigmented lesions

Pigmented (blue/brown) lesions in the mouth are common and often arise through 'tattooing' of the mucosa from an existing or previous amalgam dental filling. Despite this, mucosal melanoma (although very rare) is a diagnosis not to be missed. A common cause of a brown midline patch of the tongue is 'black hairy tongue'. This in itself is a benign condition of filiform papillae (taste buds) overgrowth, which traps pigments from food, bacteria and yeast. It can be improved by scrubbing using a toothbrush on the area with a bicarbonate-based toothpaste. A similarly named condition but different in appearance is 'hairy oral leukoplakia' of the tongue. This may be a presenting feature of HIV infection (due to oropharyngeal EBV infection) or immunosuppression and is characterised by fine white corrugated ('hairy') lines typically on the lateral edges of the tongue.

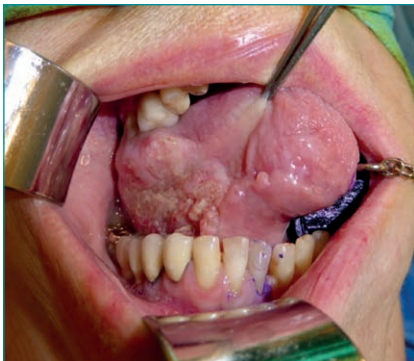### 5.3 LUMPS AND SWELLINGS IN THE MOUTH

#### SINISTER FEATURES:

- A lump in the upper lip and soft palate is malignant until proven otherwise
- Associated ulceration
- Fixity to deep tissues
- Irregular border
- Lymphadenopathy
- Nerve weakness/altered sensation of the tongue or lip/cheek
- On high-risk areas (lateral tongue, floor of mouth, retromolar)
- Previous oral cancer
- Rapidly growing
- Strong risk-factor history (smoking, ETOH, betel-nut chewing)

#### Malignant causes of swelling

In all presentations of a 'lump in the mouth', cancer must be ruled out first and foremost. Oral cancer is discussed in section 5.4 in more detail. Squamous cell carcinoma (SCC) is the commonest type of mouth cancer and typically presents as a non-healing ulcer which then becomes indurated and fixed to underlying structures, eventually taking on the form of a 'lump'. Salivary gland tumours may also occur in the mouth. The site of a salivary gland tumour has a significant influence on the likelihood of it being malignant – a general point to remember is that **the smaller the gland, the greater the chance of malignancy**. Lumps in the **upper lip** and the junction of the hard and soft palate are particularly risky; they are therefore presumed malignant until proven otherwise.



*Figure 5.9: This patient presented with an advanced oral cancer. This would require an extensive resection, neck dissection and reconstruction, often with free tissue transfer otherwise known as 'free flaps'. Picture courtesy of Mr. M. Ethunandan*

Malignant jaw tumours may be primary or secondary/metastatic in origin. Whilst SCC arising in the mouth and invading into bone is most common, metastasis of distant tumours to the craniofacial skeleton also occurs as with metastases to other bones in the body (from the breast, lung, kidney, thyroid, colon or prostate). Rarely, malignant primary bone tumours may be odontogenic in origin (from tooth tissue), such as ameloblastic carcinoma, though as mentioned these are very rare in comparison to SCC.

## Benign Causes of Swelling

### *Infection*

Infected teeth often lead to periapical (tip of the root) abscess formation, which in turn can track along the path of least resistance to the gingival surface. This presents as a dental sinus or 'gum boil'. Teeth with associated periapical infection will be tender to percussion (tapping with the end of a metal instrument) and warrant treatment by a dentist.

### *Fibroepithelial polyp*

In the absence of an obvious dental infection, a fleshy mobile lump on the gingiva or mucosa is commonly a fibroepithelial polyp. These are believed to be caused by a form of chronic irritation, be that occlusal trauma to the cheek or persistent rubbing of a denture.

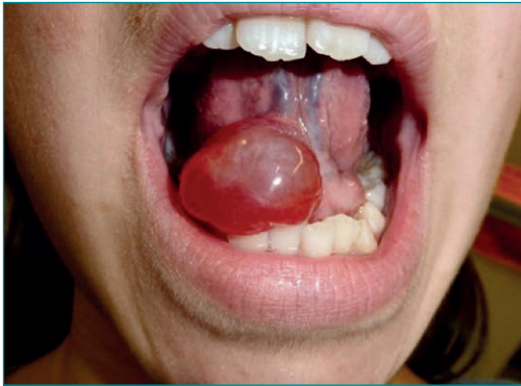Diagnosis can usually be achieved by examination alone; however, only histological assessment can confirm for definite. As such, these lesions are treated by excisional biopsy.

Something very similar is seen in patients with dentures whereby chronic irritation by the edge of the denture can cause the formation of a painless, often lobulated mass. This is instead called denture-induced hyperplasia. It is treated the same way as a fibroepithelial polyp, with the addition of adjusting the denture to prevent the ongoing source of irritation.

### *Mucocele/ranula*

A mucocele is a collection of saliva extruding from a minor salivary gland into surrounding connective tissues. A ranula is a generally larger mucocele of the floor of the mouth and by definition arises from a sublingual gland. Mucoceles are generally harmless but can become infected and can also be a nuisance to patients, especially as they expand to become very large. These can therefore usually be managed by minimally invasive procedures under local anaesthetic or, for the more stubborn lesions, excision of the affected sublingual gland.

Remember – upper-lip lumps are more likely to be neoplastic or cancerous and always warrant investigation.

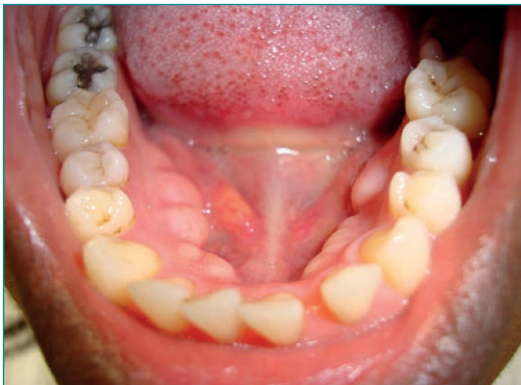

*Figure 5.10: This is a ranula, a collection of saliva in the floor of the mouth. Sometimes they can herniate into the neck, otherwise known as a plunging ranula. Picture courtesy of Mr. M. Ethunandan*

### **Bony exostosis – tori**

A simple hard lump of the mandible or maxilla is often described as a ‘torus’. These are physiological bony outgrowths (exostoses) of indefinite duration (for as long as the patient can remember) usually found as either a symmetrical smooth midline swelling of the hard palate, or bilateral symmetrical smooth swellings of the mandible, most often inside the jaw (on the lingual side).

Without any sinister features or ambiguity over the clinical diagnosis, these lesions can be monitored. Any change in its appearance, however, would suggest a pathological swelling and warrants further assessment.



*Figure 5.11: This is a classic picture of bilateral lingual tori. They appear as smooth, hard swellings. There is also a yellowish right submandibular duct stone visible under the mucosa. Picture courtesy of Mr. S. Walsh*

## 5.4 ORAL CANCER

In the last thirty years there have been incredible advances in patient education, diagnosis and subsequent management of oral and oropharyngeal cancer, yet this has only been met with a minor improvement in the survival of patients. This is commonly attributed to late presentation.

### SCC

As with any cancer, the development of SCC is a multi-step process involving a cascade of oncogenes and the failure of tumour suppressor genes, of which p53 is most commonly acknowledged.

There are numerous rare causes of oral/oropharyngeal SCC such as a diet low in antioxidants and vitamins A and C, trauma and infection (EBV and syphilis). However, without doubt the two most common causes are tobacco smoking and alcohol, which have a synergistic effect (in other words, the harmful effect of these two risk factors combined is more harmful than simply the sum of their individual effects). The long-term use of betel nut (gutkha) can lead to SCC in oral submucous fibrosis.

Human papilloma viruses (HPV) 16 and 18 spread by the genito-oral route have also become directly implicated in the development of not only oropharyngeal (tonsil and base-of-tongue cancers) but also (less commonly) SCCs limited to the mouth (oral cavity) alone. Consequently, the disease is now presenting in younger adults and with greater balance between genders. The HPV vaccination now offered to both male and female school-age children is thought to have a protective effect against developing HPV-related head and neck cancers.

### Assessment and staging

The presentation of mouth cancers is described in sections 5.2 and 5.3. Once a suspicious lesion is identified, we need to confirm the diagnosis by an incisional biopsy (typically under local anaesthetic), which also gives some idea about the tumour aggressiveness, followed by tumour staging. The latter involves clinical examination and cross-sectional imaging to give more detail regarding the presence of local, regional and distant spread. Imaging typically includes one or a combination of the following:

- CT neck and thorax with IV contrast (from the skull base down to the diaphragm, highlighting the primary tumour in the mouth, any involved lymph nodes in the neck and any likely lung metastases)

- Ultrasound-guided core biopsy (or fine needle aspiration) of any palpable neck lump
- MRI to evaluate for spread along nerves and involvement of bone marrow of the jaws.

For some small tumours with no evidence of regional or distant spread, and in cases where we don't need access to the neck to allow for reconstruction with free tissue transfer, sentinel lymph node biopsy should be offered to the patient. This involves the use of radiotracer dyes that are injected into the primary tumour, combined with the use of an intra-operative gamma camera (radiation sensor) to locate and biopsy the first-draining ('first echelon') lymph node. This method helps to determine whether or not neck dissection surgery is needed, or just a simple excision of the mouth tumour. Some surgeons use this staging technique routinely, while others do not, for fear of missing spread of cancer to other lymph nodes in the neck (which is reported to occur in about 20–30% of small oral SCCs). For this reason, some surgeons even suggest that all (even the smallest) oral SCCs should be treated with elective neck dissection as this is proven to increase disease-specific (avoiding death from the mouth cancer) and overall survival (avoiding death for any reason).

Like other cancers in the body, mouth cancers are staged with the TNM system:

- T – describes the primary tumour,
- N – describes the regional lymph node involvement, and
- M – describes the presence or absence of distant metastases.

This gives the MDT an idea of the extent of the disease, treatment needs and prognosis.

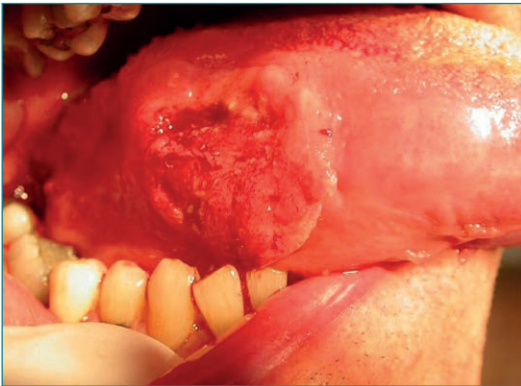
### Treatment

In the mouth, surgery is the mainstay of cancer treatment. Primary radiotherapy (using radiotherapy as the main treatment) can be considered in some instances, but generally speaking, it is used less commonly than other modalities due to its associated morbidity and the associated difficulty with patient compliance over a typical six-week course. Even with surgical treatment, postoperative radiotherapy may still be required for large and/or aggressive cancers.

Because of the variety of ways in which oral cancers can present anatomically and because most oral cancers present in a later stage (T3 or T4), cancer surgery performed by oral and maxillofacial surgeons is typically variable. This commonly requires aggressive major surgery to remove all tumour tissue

with a surrounding safety margin of normal tissue in combination with neck dissection. The aggressiveness of the surgery means that a temporary tracheostomy is often performed at the beginning of the surgery to protect the patient's airway from bleeding and swelling of the throat in the immediate postoperative period. Furthermore, because of the large volume of tissue removed (and the impact upon facial aesthetics and oral function such as chewing and swallowing), complex reconstructions are often needed. In current practice, this usually means that a pair of oral and maxillofacial surgeons perform the surgery together. One will remove the cancer while, at the same time, the other harvests tissue from elsewhere on the body to auto-transplant it into the head and neck region, re-vascularising it by anastomosing (sewing together) the small 2–3mm diameter artery and vein(s) of the transplanted tissue to arteries and veins in the neck, under a surgical microscope. This is known as free-tissue (or free-flap) reconstruction and is performed in almost all UK head and neck cancer centres.

Oral and maxillofacial surgeons performing major free-flap reconstructions regularly use a variety of flaps, depending upon the type of tissue that needs to be replaced. For example, this may simply involve the replacement of soft tissue only (for example using a radial forearm free flap or anterolateral thigh flap) or in more complex reconstructions, the replacement of both soft tissue and bone (for example using free flaps of the fibula, scapula or iliac crest to reconstruct large defects of facial skeleton or skull base).



*Figure 5.12: This patient presented with a biopsy-confirmed SCC of the right lateral tongue. As well as requiring a neck dissection, treatment would have consisted of resection of a large portion of the right side of the tongue. Picture courtesy of Professor P. Brennan*

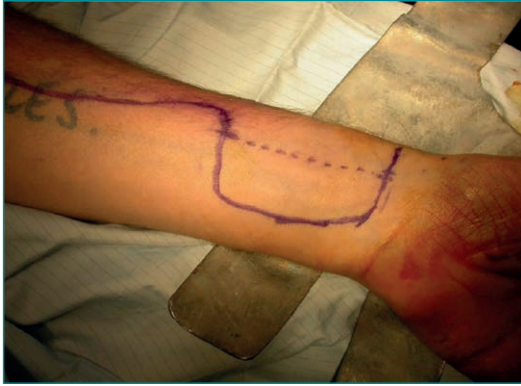


Figure 5.13: In order to restore form, function and aid in speech, eating and swallowing, a radial forearm free flap from the patient's non-dominant arm would have been raised. Here you can see the surgeon's markings prior to commencing surgery. Picture courtesy of Professor P. Brennan

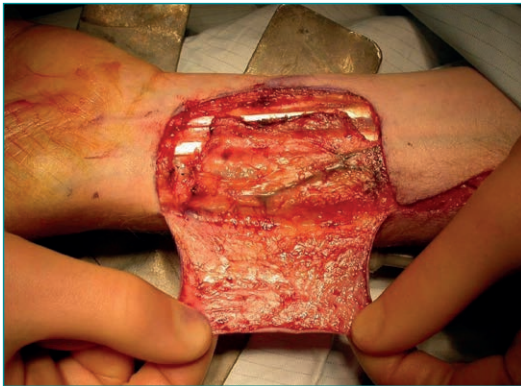


Figure 5.14: Here you can see the surgeon raising the flap. Notice the tendons of palmaris longus and flexor carpi radialis! Pictures courtesy of Professor P. Brennan

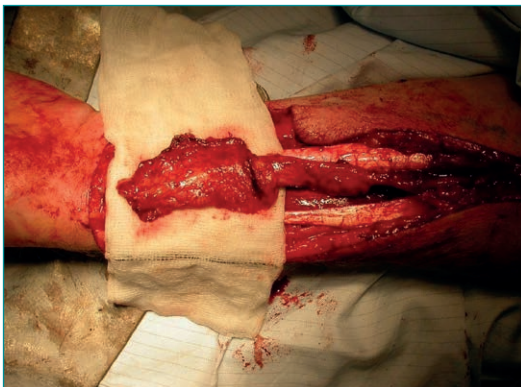
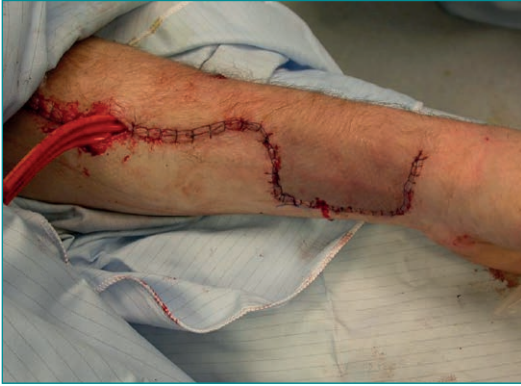
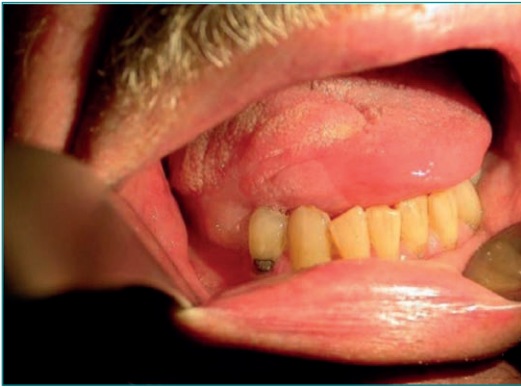
Figure 5.15: Here, the flap is fully raised. You can see the blood supply or 'pedicle' attached and travelling up to the patient's elbow, where it would later be disconnected prior to transfer to the neck for anastomosis. Picture courtesy of Professor P. Brennan

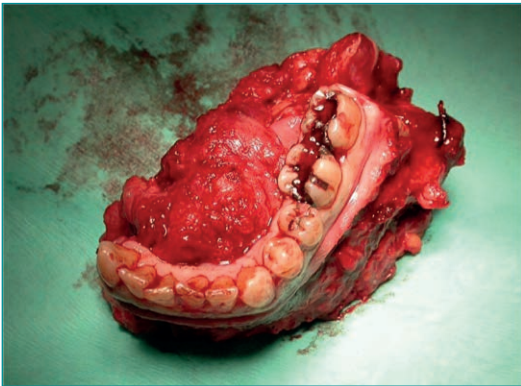




*Figure 5.16: The donor site is closed. All surgeons will use drains and monitor the limb for any signs of vascular or neurological compromise. Picture courtesy of Professor P. Brennan*



*Figure 5.17: This is the patient six months post-surgery. Look how well the radial forearm free flap has integrated. It actually looks like a tongue! Picture courtesy of Professor P. Brennan*



*Figure 5.18: This patient presented with an extensive floor-of-mouth SCC invading the mandible. In order to achieve surgical clearance of the tumour, part of the patient's mandible needed to be resected as part of the specimen. Picture courtesy of Professor P. Brennan*

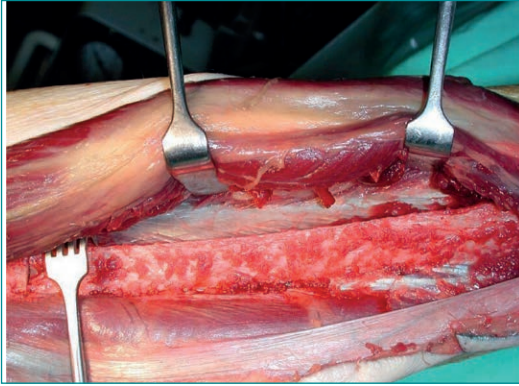


Figure 5.19: In order to restore form and function, a fibula free flap was raised. Picture courtesy of Professor P. Brennan

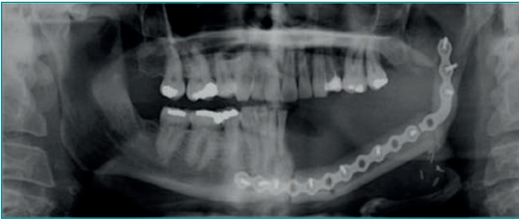


Figure 5.20: This postoperative OPG shows how the fibula bone has been cut or osteotomised to fit the existing profile of the patient. As well as anastomosing the vessels to vessels in the neck, it is secured with plates and screws slightly larger than that normally used in most trauma cases. Picture courtesy of Professor P. Brennan

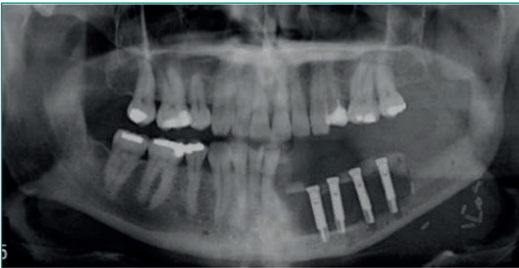
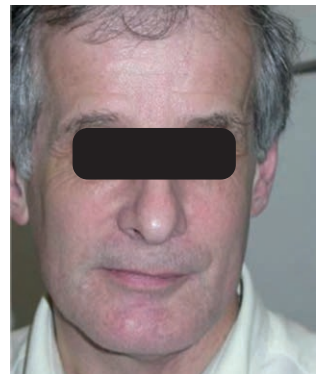
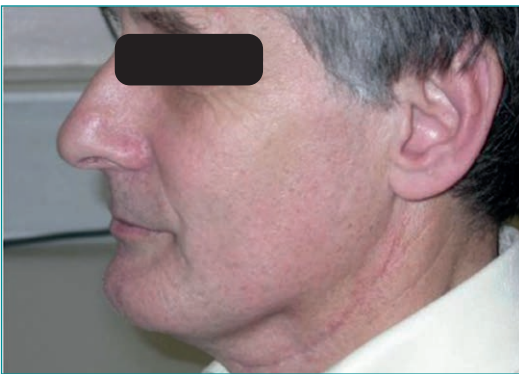

Figure 5.21: Several months later, the patient has gone on to have osseointegrated implants that can be seen on the OPG. Prosthetic teeth can be fitted on these implants to help the patient masticate. Picture courtesy of Professor P. Brennan



Figures 5.22 & 5.23: These pictures are several months post-surgery. The patient is free from disease, has had a new mandible reconstructed from his fibula and new teeth to eat with. Picture courtesy of Professor P. Brennan

## 5.5 DENTAL SURGERY

Dentoalveolar surgery is what many would class as ‘oral surgery’. By its name, it relates to management of the teeth and the immediate surrounding tissues (gingiva, periodontium and alveolar bone of the jaws) and typically involves the following:

- Exodontia (extraction of teeth, including impacted / orthodontically crowded teeth and removal of root apices for infection)
- Removal of jaw cysts
- Osseo-integrated dental implants.

The technicalities of dental extraction are beyond the scope of this book but are taught within the dental undergraduate curriculum. Teeth may need to be extracted as a consequence of acquired pathology, be that dental caries (tooth decay), periodontal (gum) disease, infection (abscess) or cyst formation secondary to various dental pathologies. Furthermore, teeth may need to be removed to augment other treatments, such as providing surgical access to a jaw tumour or to aid corrective orthodontic treatment of a dentally ‘crowded’ jaw.

Impaction is where a tooth is unable to erupt into the mouth fully, and is unlikely to do so in the longer term. Not all unerupted teeth are impacted and the patient’s age and therefore expected tooth eruption dates aid the diagnosis. Some impacted teeth can simply be monitored by a dentist, but those at risk of, or with, complicating factors such as cyst formation, infection or other pathology may need surgical removal (by drilling away surrounding jaw bone to provide access to, and removal of, the offending tooth/teeth).

Third molars (more commonly known ‘wisdom teeth’) are the commonest teeth to impact (especially when they are partially exposed/erupted in the mouth) and may lead to pericoronitis – a common source of discomfort to young adults. Here, the gums around the lower wisdom tooth (third molar) become infected (typically described as an inflamed ‘operculum’), which surrounds the impacted tooth, trapping commensal organisms such as *Peptostreptococci* and *Bacteroides* species. Early on, this infection can present with discomfort and halitosis and can be treated simply with antiseptic mouth rinses. However, it may progress to the development of a severe life-threatening neck-space infection causing dysphagia (difficulty swallowing and therefore drooling), odynophagia (painful swallowing) and trismus (reduced mouth opening because of involvement of the masticator/chewing muscles) with accompanying tender swelling of the neck (discussed further in section 7.2).

Impacted canine teeth often present as missing teeth or palatal or buccal lumps/swellings in late childhood/early teens. Maxillary canines should erupt between 11–12 years of age. High-street general dentists routinely palpate for their presence around the age of 10 years. Removing the deciduous (primary dentition) canine by the age of 10 can help the adult canine spontaneously erupt. However, if the adult version does not erupt, then this can complicate with jaw cyst formation and damage to adjacent teeth, as well as functional and aesthetic problems. The oral and maxillofacial surgeon may be called upon (by an orthodontist) to help by extracting the canine, removing teeth/structures in its way or by drilling through the jaw to expose the tooth and attach a small chain with which the orthodontist can gradually pull the tooth into position over a matter of weeks/months.

Apicectomy is a procedure sometimes performed when a conventional root canal filling (performed by a dentist) fails because of ongoing periapical infection (around the tip of the tooth root). In an attempt to avoid further infection and loss/removal of the tooth, this procedure involves removal of the root apex through a window drilled in the jaw bone, followed by placement of some filling material into the root canal in a retrograde manner (i.e. by filling it from the root side of the tooth rather than through the tooth crown itself).

Attempts to replace missing teeth are reported as far back as 600BC. Ever since the 1960s there has been huge progression in the use of dental implants, to the point that oral and maxillofacial surgeons commonly place osseo-integrated titanium dental implant fixtures. This can be done for major reconstructions (for example placing implants into a jaw reconstructed with a fibula free flap). Implants can also be placed in isolation (with or without the additional use of bone graft material) when replacing teeth for simpler functional and aesthetic reasons (usually in conjunction with a restorative dentist who deals with the non-surgical aspects).

## 5.6 CLEFT LIP AND PALATE

Cleft lip and palate is the most common congenital craniofacial deformity and occurs in between one in 700 to one in 1,000 births. Cleft lip, with or without cleft palate, and isolated cleft palate are considered two very separate clinical entities.

While there are a number of syndromes associated with cleft lip and palate, and cleft palate, the pathogenesis of cleft is multifactorial. The majority of cleft lip and palate cases are isolated non-syndromic birth defects; however, a small proportion are part of a syndrome such as hemifacial microsomia. Cleft lip alone accounts for around 25% of cleft lip and palate cases. Cleft palate can present with a varying range of severity from partial to complete clefting of the soft and hard palate. Unlike cleft lip and palate, isolated cleft palate has a far greater association with syndromes such as Van der Woude syndrome, Stickler syndrome and DiGeorge syndrome. You will probably never come across these rare syndromes during your studies!

### Assessment

Historic improvements in antenatal ultrasound mean that cleft lip and palate can now be diagnosed as early as 12 weeks gestation, but sensitivity increases from week 20 onwards. Although antenatal diagnosis is most common, ultrasound is poorly sensitive in identifying an isolated cleft palate. Furthermore, a significant proportion of cleft lip and palate is still diagnosed at birth as part of the newborn baby assessment.

### Management

The management of cleft lip and palate is multidisciplinary, requiring the input of cleft surgeons, otologists, paediatricians, orthodontists, speech and language therapists, and specialist nurses. From the surgeon's point of view, surgery is done throughout the child and young adult's lifespan and involves meticulous management of skin, mucosa, musculature and bone in order to achieve anatomical harmony (see table below).

Age	Treatment
3–4 months	Cleft lip repair
8–15 months (typically at 6–9 months in the UK)	Cleft palate repair
6–13 years	Alveolar bone grafting followed by orthodontics
12–21 years	Orthognathic surgery Rhinoplasty Revisional surgery (e.g. pharyngoplasty)

*Table: Timing of surgical procedures in cleft patients*

Newborns often have a capacity to compensate for their cleft whilst suckling and their swallowing is otherwise normal, but sometimes modified feeding devices are needed in the first few months. Nevertheless, cleft lip can make a lip seal difficult: lip repair is performed at approximately three months of age and is based upon some key principles:

1. Excision of poor-quality tissues at the margins of the cleft
2. Approximate the lip segments whilst preserving natural landmarks e.g. cupid's bow
3. Place scars along natural lines to try to make them as inconspicuous as possible
4. Restore symmetry to the lip, nostril margins and alar bases
5. Account for vermilion height deficiency in the cleft side by recruiting tissue from the lateral lip.

Repair of the cleft palate from eight months onwards is principally for the development of future intelligible speech (and avoiding air rushing through the palate and out of the nose, known as hyper-nasal speech). The aims of a functional palatal repair are as follows:

1. Achieving normal, intelligible speech
2. To aid feeding
3. To prevent restriction of maxillary growth.

Palatal muscles are dissected from their tethered abnormal muscle insertions into the nasal and oral mucosa. Most importantly, repositioning the levator veli palatini muscle recreates the 'levator sling', a continuous band of muscle across the soft palate which partly recreates the velopharyngeal sphincter (allowing control of the desired airflow through the mouth or nose into and out of the pharynx, and therefore control of the nasality of speech).

Velopharyngeal insufficiency presents with hyper-nasal speech and abnormal findings on videofluoroscopy and nasoendoscopy.

For speech problems that cannot be managed by speech therapy alone, pharyngeal obturators or further surgery to restrict nasal air escape may be needed (such as pharyngoplasty).

Alveolar bone grafting is needed when the cleft involves the tooth-bearing bone, without which a persistent oronasal fistula (connection between the mouth and nose with leakage of fluids between) will result.

### **Subsequent and ongoing care**

Throughout childhood, the MDT work further on speech, feeding, hearing, growth and management of other associated congenital disorders (if present). Cleft patients may have complex physical and mental needs throughout their adult lives as well, requiring a very holistic approach to care. In early adulthood, functional and aesthetic problems of the jaws and nose require orthognathic surgery (sometimes involving distraction osteogenesis) to address the hypoplastic maxilla (retrusive upper jaw) and septorhinoplasty (possibly multiple nasal surgeries) for the associated complex nasal deformity.



*A man about to undergo surgery for parotid adenocarcinoma.*

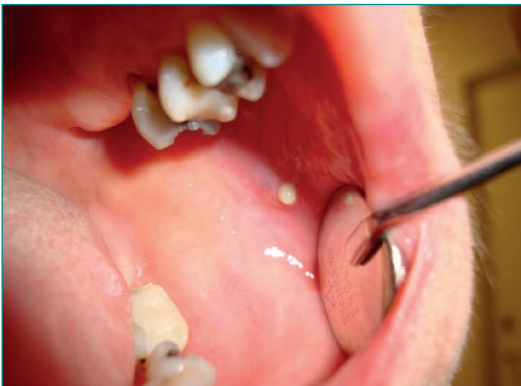

# CHAPTER 6: SALIVARY GLANDS, THE FACIAL NERVE AND FACIAL PAIN

## 6.1 ANATOMY

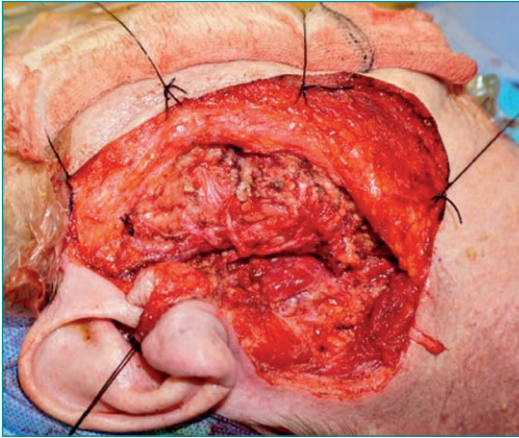
Saliva has an important biological function, representing the start of the digestive process and mechanical lubrication of food within the mouth. In addition, it is protective to the oral mucosa and teeth. Aside from minor oral salivary glands, three paired major salivary glands produce the majority of saliva – the parotid, submandibular and sublingual glands.

*Parotid glands* – These glands predominantly produce a serous type of saliva. They are located on either side of the face, anterior to the ear, and extend downwards under the earlobe and around the posterior border of the mandible. Saliva produced by the parotid drains into the parotid duct, which pierces the buccinator muscle and opens into the oral cavity opposite the upper second molar tooth. If you look inside your mouth, you will see a small papilla at this site, which represents the duct opening.



*Figure 6.1: Here you can see the opening of the parotid duct opposite the upper second molar. Interestingly, frank pus is coming from the duct. This is usually in keeping with parotitis. Picture courtesy of Mr. S. Walsh*

For oral and maxillofacial surgeons, the most important anatomical characteristic of the parotid gland is the intimate relationship with the facial nerve, a branch of which runs through it – dividing the gland into anatomically relevant superficial and deep lobes. Therefore, any surgical procedure involving the parotid gland (for example a superficial parotidectomy) carries risk of trauma and injury to the facial nerve. As the facial nerve supplies the muscles of facial expression, damage to it can clearly cause significant patient morbidity.



*Figure 6.2: Here a tumour in the superficial lobe has been dissected carefully off the underlying facial nerve, which can be seen spreading out as branches from a main trunk. Underneath the nerve itself is the deep lobe of the parotid. Picture courtesy of Mr. M. Ethunandan*

*Submandibular glands* – These are located high up in the neck ‘under the mandible’ and wrap around the free edge of one of the muscles that form the floor of the mouth – the mylohyoid. They produce a more mucous-like, thicker saliva, which drains into the oral cavity via the submandibular – or Wharton’s – duct, which opens on either side of the lingual frenum, that vertical fold of skin under your tongue.

*Sublingual glands* – The last set of major salivary glands are the sublingual glands, which exist in the floor of the mouth. They are each the size of a walnut and drain either directly into the mouth, or into the submandibular duct. Surgeons become concerned with the sublingual glands because the lingual nerve, supplying sensation and taste to the anterior two-thirds of the tongue, runs close by. Thus, any surgery to this gland carries a risk to the nerve.

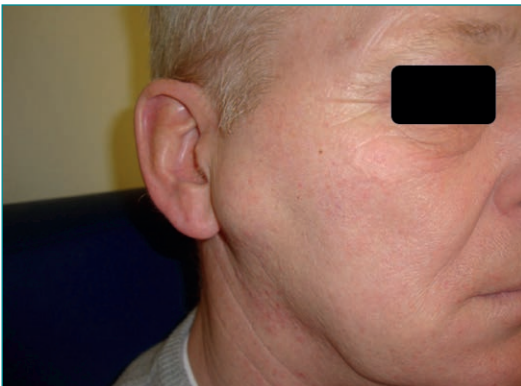## 6.2 SALIVARY PATHOLOGY

So what can go wrong with salivary glands? Like any glandular tissue, the salivary glands can grow in an abnormal fashion, causing a mass or tumour, or become obstructed (i.e. by a salivary stone).

### 6.2.1 SALIVARY TUMOURS

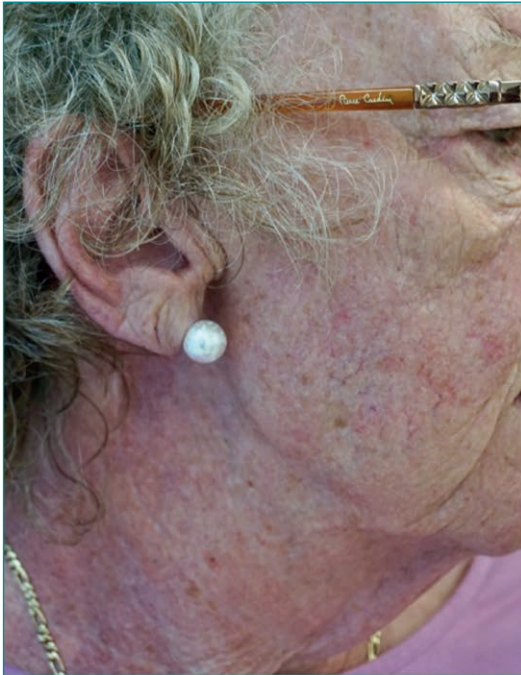Salivary gland tumours can be either benign or malignant. In general, there is an intriguing relationship between the size of a gland and the risk of a tumour within it being malignant – **the smaller the gland, the greater the chance of a malignant tumour**. To illustrate, 20% of parotid gland lumps will be malignant, compared with 50% in the submandibular gland and 85% of sublingual gland tumours. In other words, only 15% of sublingual gland tumours are benign. That said, it is important to emphasise that salivary gland cancers are rare, representing only 1% of malignant tumours of the head and neck. The rule of 80s is a useful tool for any medical student: 80% of salivary tumours are in the parotid, 80% of parotid tumours are benign and 80% of these are pleomorphic adenomas.

Most salivary tumours present as a painless mass – often they are slow growing, but some, particularly malignant tumours, can be painful or grow quite rapidly. It is important when assessing a lump that might originate in the salivary glands to note any presence of facial nerve involvement or any cervical lymphadenopathy, as these are worrying signs of a more sinister tumour. You will also remember the mantra at the end of any neck examination to look inside the mouth for any deep-lobe parotid extension which might be seen as a swelling in the pharyngeal wall!

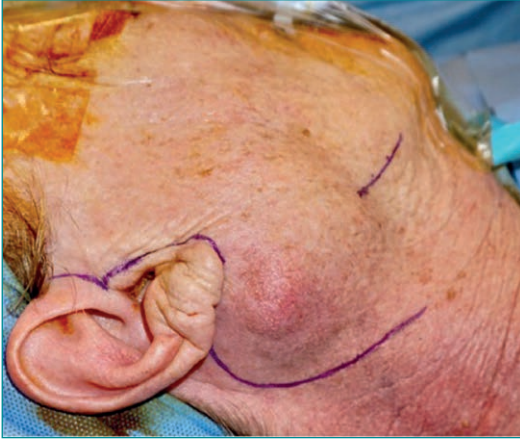

*Figure 6.3 This patient presented with a slow-growing, painless mass in the right parotid. It is essential to assess the facial nerve in such patients! Picture courtesy of Mr. S. Walsh*

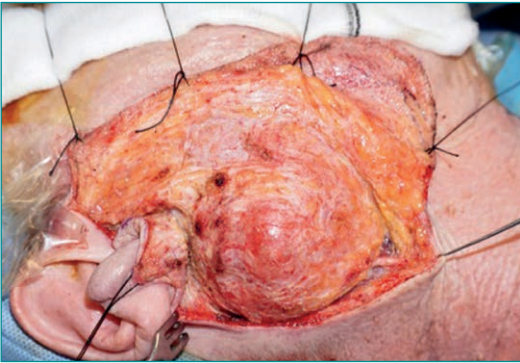
A salivary gland mass will routinely be assessed by an ultrasound scan (USS) with or without fine needle aspiration cytology (FNAC). Depending on the pathology, CT and MRI scans will also be used to give a more detailed view of the mass and its extension within the salivary glands. With malignant disease, USS, CT and MRI can all be helpful in determining any lymph node involvement. As with all head and neck cancer, malignant salivary gland cancers are staged using the TNM system, where the size of the tumour (T), the presence of cervical lymph nodes (N) and the development of distant metastasis (M) are all important factors that determine management and prognosis. This information often dictates whether these tumours can be removed surgically or require other adjunctive treatment, such as removal of the draining lymph nodes in the neck or chemo-radiotherapy.



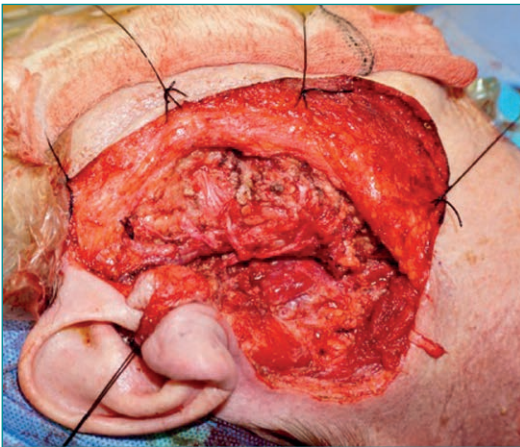
*Figure 6.4: This patient presented with a palpable lump in the right parotid gland. Picture courtesy of Mr. M. Ethunandan*



*Figure 6.5: An incision is made around the ear, into the neck. We do our best to hide the incisions in such a way as to make them inconspicuous. Picture courtesy of Mr. M. Ethunandan*



*Figure 6.6: A flap of skin and a fascial layer, called SMAS, lifted to expose the parotid capsule, in which the tumour is located. Picture courtesy of Mr. M. Ethunandan*



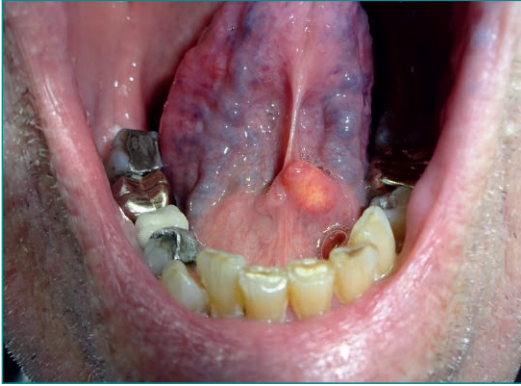
*Figure 6.7: The tumour is dissected carefully off the underlying facial nerve, which can be seen spreading out as branches from a main trunk. Picture courtesy of Mr. M. Ethunandan*

A mass in the submandibular or sublingual salivary glands, either benign or malignant, will be surgically treated with gland excision – a relatively common procedure. When you get to the parotid gland, things start to get more interesting and controversial. The jury is still out as to the best treatment plan for a benign superficial lobe parotid mass (i.e. a pleomorphic adenoma), with evidence for and against just removing the lump itself (termed an extracapsular dissection, ECD, which is a less invasive procedure) or removing the entirety of the superficial lobe (a superficial parotidectomy). The later procedure involves formal identification of the main trunks of the facial nerve, thus in theory minimising the risk of facial nerve injury. Surgery to a malignant parotid mass will require a clear margin of tissue to be excised, and in some cases may require sacrifice of the facial nerve. The advantage of an ECD is a smaller incision and reduced risk of gustatory sweating (Frey's syndrome), which can occur after parotid surgery. More about that later.

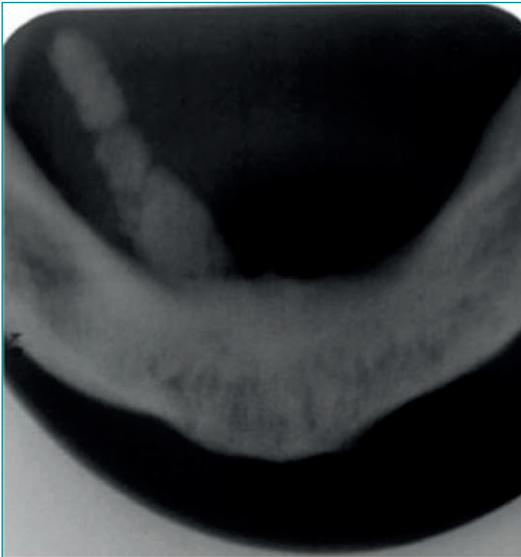
### 6.2.2 OBSTRUCTIVE DISEASE

The salivary ducts are prone to becoming blocked by stones that can precipitate from the saliva within them (sialolithiasis). Their formation is multifactorial, but when they grow large enough, they occlude the duct system within the gland. This classically presents with a 'mealtime' syndrome. Here, when patients salivate – typically when they are about to eat – and the saliva production increases, the saliva flow is impeded, causing a build-up of pressure and resulting pain. Often patients report a foul discharge or even a gritty sensation in their mouth. This pattern is repeated whenever the patient eats. Sometimes, because saliva is stagnant in the gland, the gland can get inflamed or infected, which often requires urgent management, either via intravenous antibiotics or even surgical drainage. Narrowing or stenosis of salivary ducts can also present with obstructive symptoms.

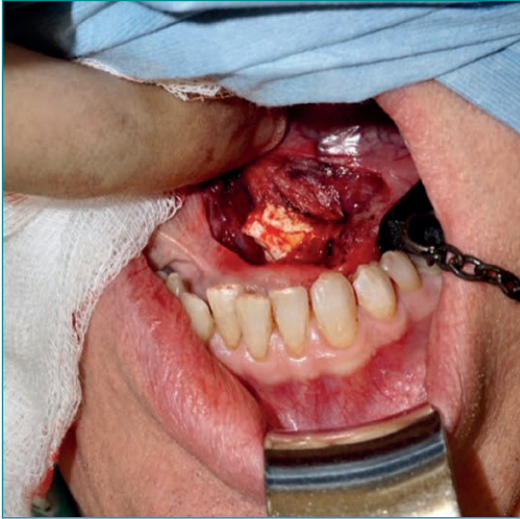
An USS is a useful first-line investigation for patients with these problems, but other radiographic techniques can be used. For example, a sialogram is a method where contrast material is introduced through the duct orifice with a blunt-ended catheter to delineate the duct anatomy and more clearly mark out any obstruction. Some surgeons use endoscopic techniques to identify and retrieve stones from the duct. In the case of the submandibular and sublingual glands, when stones are large or located further towards the gland, we usually have no option but to surgically remove the entire gland.



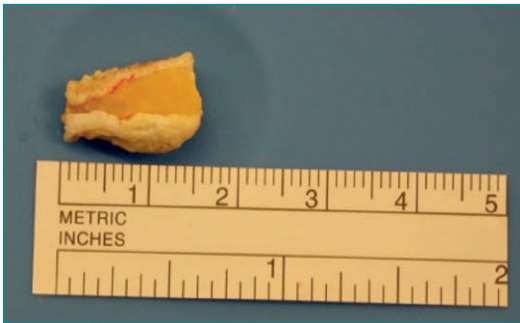
*Figure 6.8: Here you can see a salivary stone or calculus in the floor of a mouth, just beneath the surface of the mucosa. They travel along the path of the submandibular duct but sometimes get trapped. Picture courtesy of Mr. S. Walsh*



*Figure 6.9: Sometimes salivary calculi or stones are visible on plain film x-rays. This is called an occlusal radiograph and clearly shows a stone in the floor of the mouth. Picture courtesy of Mr. A. Sidebottom*



*Figure 6.10: This is a different patient, who would have presented with a blocked right submandibular duct. Incising into the floor of the mouth allows retrieval of the stone. Picture courtesy of Mr. M. Ethunandan*

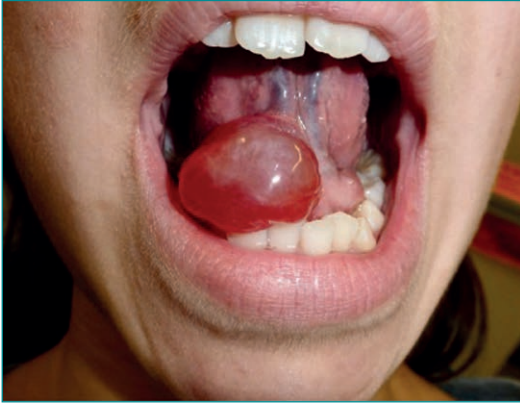

*Figure 6.11: This is the same calculi. Very much like renal calculi, these can cause obstructive symptoms and cause extensive swelling in the associated gland. Picture courtesy of Mr. M. Ethunandan*

### 6.2.3 TRAUMA

As with any of the facial structures, the glands can be involved in a traumatic injury, either directly (e.g. from a stab wound) or indirectly, via blunt force trauma. As discussed elsewhere, a mucocele – one of the most common small lumps occurring in the mouth – is a result of trauma to a minor salivary gland, often on the lip. Sometimes, when this affects the sublingual gland, it leads to a dramatic-looking, bluish swelling in the floor of the mouth, which (apparently!) resembles a frog's neck and has been accordingly termed a ranula.





*Figure 6.12: This is a ranula, a collection of saliva in the floor of the mouth. Sometimes they can herniate into the neck, which is known as a plunging ranula. Picture courtesy of Mr. M. Ethunandan*

Saliva can leak out directly from the gland into the neighbouring tissues, creating a salivary collection or sialocele. Often this is a result of iatrogenic trauma (i.e. surgery to the gland), commonly affecting the parotid gland. Another common complication that might arise from parotid surgery or injury is Frey's syndrome, sometimes described as 'gustatory sweating'. Normally, the parotid gland is supplied by parasympathetic secretomotor fibres from the glossopharyngeal nerve (via the otic ganglion). The skin's sweat glands are supplied by sympathetic nerve fibres (from the thoracic ganglion). Injury/surgery to the parotid gland and overlying skin means that there is 'cross wiring' of salivary secretomotor fibres with secretomotor fibres of sweat glands, such that upon eating, the patient suffers from sweating.

### 6.3 FACIAL PAIN

A patient presenting with facial pain or altered sensation can be extremely difficult to diagnose and treat. Whilst organic causes may be obvious and can be treated accordingly, often there is a strong psychological component that can be difficult to overcome. However, dental pathology is still the most common cause of facial pain and a detailed history and examination may warrant prompt assessment by the patient's dentist.

If the pain is not characteristic of a dental cause, then a thorough pain history is required. With an understanding of the different aetiologies of facial pain, your history will become more focused. Ask if the pain is intermittent or episodic in nature; does it 'shoot' down the face in the distribution of the trigeminal nerve, is the pain there at night, is the pain associated with earache or sinusitis? In addition, a past medical history should include asking about other neurological disorders and mental health. Examination should include the face, mouth, nasal cavity, neck and cranial nerves.

#### Non-dental benign facial pain syndromes

Unfortunately, this list is extensive and, to confuse matters further, specialists in this area have a bad habit of changing the terminology for such conditions every few years. Below, we discuss the common causes of facial pain, which are frequently referred to OMFS units across the country.

#### 6.3.1 TEMPOROMANDIBULAR DISORDER

As seen in the previous chapter, temporomandibular disorder (TMD) is an umbrella term describing dysfunction of the temporomandibular joint and associated muscular apparatus that causes pain and symptoms of the jaw joint and face.

#### 6.3.2 TRIGEMINAL NEURALGIA

The symptoms of trigeminal neuralgia are well described. Classically, it produces a sharp 'lightning'- or 'shooting'-like pain in the distribution of one of the divisions of the trigeminal nerve (ophthalmic, maxillary, mandibular) and typically occurs in 'bursts' lasting seconds at a time. The pain often has a specific trigger (e.g. touch or temperature) and does not cross the midline. Despite being brief in nature, it can be debilitating and is often described as the worst pain the patient has ever experienced. Patients live in fear of it reoccurring.

Examination is fairly unremarkable. The only exception to this is that patients with triggers may become increasingly anxious that you may provoke an episode of pain by examining them.

As part of the diagnostic arsenal, cross-sectional imaging, most notably MRI, is invaluable to exclude space-occupying lesions (SOL) or blood vessels compressing the trigeminal nerve in the cerebellopontine angle or, in the case of patients under the age of 40 years, for the assessment for evidence of multiple sclerosis.

Trigeminal neuralgia can be managed either medically or surgically, often dependent on the underlying cause. In medically refractory cases, if the pain can be isolated to a single division of the trigeminal nerve, then targeted treatments such as direct cryotherapy or microvascular decompression of the nerve have been shown to be beneficial. Furthermore, in the acute setting, the use of a mixture of short- and long-acting local anaesthetics can be both diagnostic and (temporarily) therapeutic to the patient.

### **6.3.3 ATYPICAL FACIAL PAIN AND BURNING MOUTH SYNDROME**

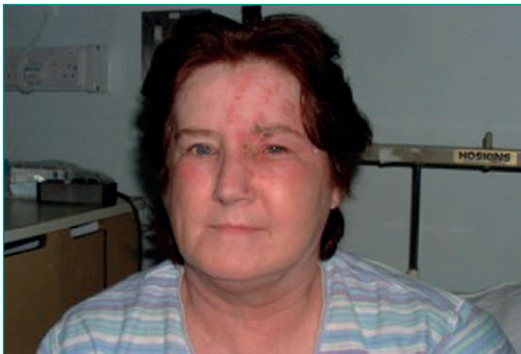In contrast to trigeminal neuralgia, atypical facial pain and burning mouth syndrome (oral dysaesthesia) represent facial pain syndromes with no organic cause, and a strong psychological component. The pain and symptoms of atypical facial pain follow no myofascial or nerve distribution, varying in character and with no recognisable pattern, but crucially do not disturb eating or sleep. Typically (but not exclusively) the patient is middle aged, female and sometimes with a psychiatric history, but this stereotype is not a hard-and-fast rule. As a diagnosis of exclusion, a detailed history, followed by an unremarkable clinical examination, can aid diagnosis.

Patients with burning mouth syndrome may also present with altered or a metallic taste. On examination, the soft tissue of the mouth will appear normal. Diagnosis is by exclusion – including blood tests for haematological and nutritional deficiencies including FBC, B12, folate and ferritin, and diabetes mellitus, and excluding candida infection. Any of the above should be treated before a formal diagnosis is made. Patients with atypical facial pain or burning mouth syndrome are typically treated with low-dose tricyclic antidepressants.

### 6.3.4 POST HERPETIC NEURALGIA

Shingles, or herpes zoster, is caused by the varicella-zoster virus. On the rest of the body its distribution is dermatomal, resulting in an eruption of a vesicular rash. On the face, it tends to be distributed along one of the three divisions of the trigeminal nerve, with no crossing of the midline.

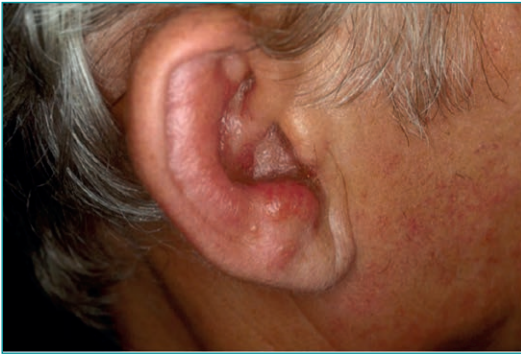As the virus can reside within neural tissue, it can cause damage with subsequent intermittent neuralgic pain along the distribution of that nerve. Patients can also show some degree of scarring in the affected disease areas. Managing this can be incredibly challenging. A number of drugs are used, including gabapentin, tricyclic antidepressants (such as amitriptyline) and anticonvulsants (like carbamazepine); however, in most cases the pain is refractory.



*Figure 6.13: This patient presented with herpes zoster in the left ophthalmic division of the trigeminal nerve (V1). Note that this does not cross the midline. This patient should also be assessed by our ophthalmology colleagues to assess the globe itself. Picture courtesy of Mr. A. Sidebottom*

## 6.4 FACIAL PALSY

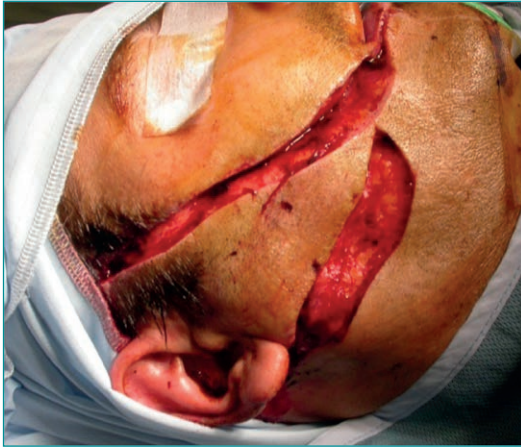Facial palsy means weakness or total paralysis of the facial muscles and can be due to many causes. The commonest is Bell's palsy, which is idiopathic (possibly inflammatory, post-viral) with a short onset (days). Ramsay Hunt syndrome is where a post-herpetic neuropathy presents with facial weakness and vesicles in the external ear canal. Other rarer causes to be aware of include congenital problems, other neurological disease (such as Guillain-Barré and multiple sclerosis), tumours (e.g. a skull-base/brain tumour or nerve sheath tumour such as a schwannoma), trauma, surgery itself, metabolic disorders (such as hyperthyroidism and diabetes mellitus) and autoimmune conditions.



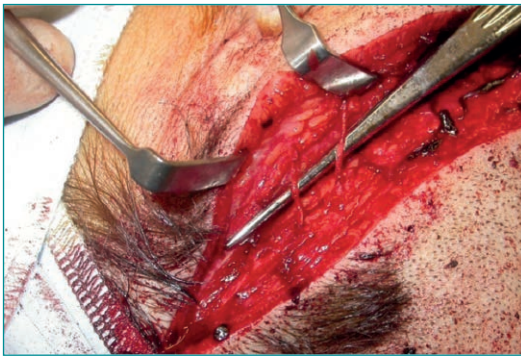
*Figure 6.14: This patient presented with right-sided facial palsy. Examination of the right ear identified vesicles in the external auditory meatus. The diagnosis: Ramsay Hunt syndrome. Picture courtesy of Mr. A. Sidebottom*

Facial palsy is graded by using the House–Brackmann scale, which ranges from 1 (normal facial function in all areas) to 6 (total paralysis). When it occurs, the most immediate concern is to protect the affected eye from drying out, which can lead to corneal abrasion/ulceration (due to loss of eye closure), by placing a protective eye shield or taping the eye shut. Depending on the underlying cause, systemic steroids and antivirals may be considered, although the evidence base is equivocal.

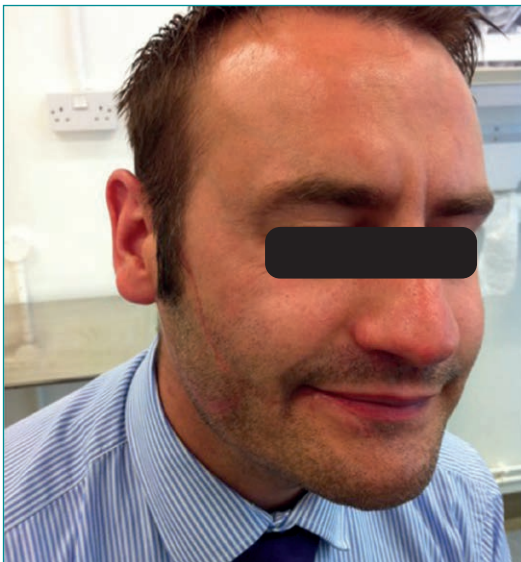Surgery is required urgently if the nerve is likely to have been traumatically severed (e.g. by a facial laceration or stabbing injury). This involves repair of the cut nerve end under a microscope with incredibly fine sutures (stitches).



*Figure 6.15: This patient suffered significant facial injuries as a result of interpersonal violence. The patient presented with facial paralysis, suggesting the facial nerve branches had been severed. Picture courtesy of Professor P. Brennan*



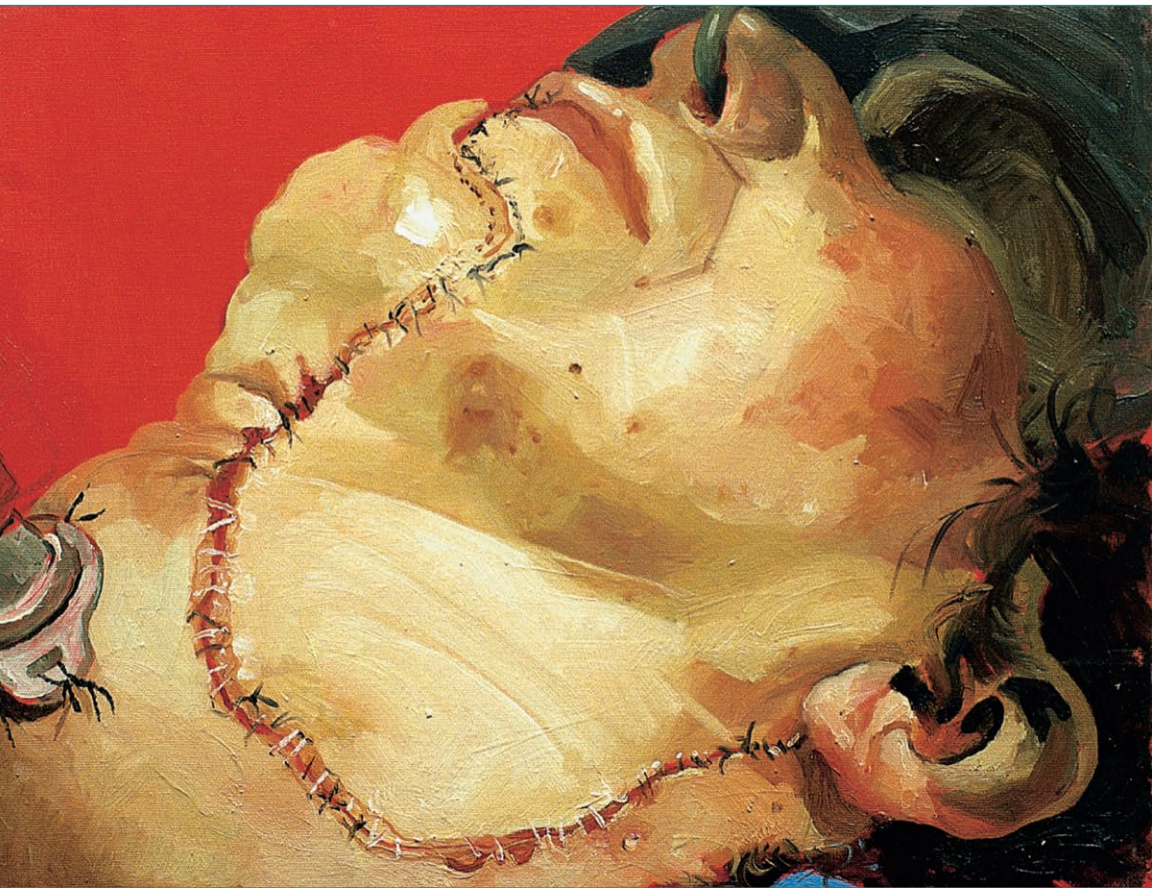*Figure 6.16: The wound was explored urgently. Here you can see two branches of the facial nerve which were repaired with the use of incredibly fine sutures under a powerful microscope. Picture courtesy of Professor P. Brennan*



*Figure 6.17: This is the same patient nine months post-injury. Notice both the symmetry in his smile, but also his ability to close his eye. This is an essential role of the facial nerve. Picture courtesy of Professor P. Brennan*

In cases of persistent nerve palsy or in those who present late, 'facial reanimation' may be required. This may involve 'static procedures' (such as forehead, brow and/or face lifts). Alternatively, 'dynamic' procedures may be performed. Dynamic procedures may involve functional muscle transfer of masticatory (chewing) muscles to help with facial movement, functional masticatory (masseter) nerve transfer to facial muscles, use of nerve grafts to repair/re-innervate the affected facial nerve, or even the transfer of free muscle flaps. Such flaps include auto-transplantation of the gracilis muscle from the groin to the face, with anastomosis (microsurgical connection) of the artery, vein and nerve supply to the corresponding blood vessels and viable motor nerve in the face/neck.

These unique dynamic reanimation surgeries have evolved over the last couple of decades with advances in microsurgery and are increasingly becoming the gold-standard treatment for severe persistent facial palsy.



*A woman at the end of lip split mandibulotomy access surgery for oropharyngeal tumour resection and reconstruction with a free flap.*



# CHAPTER 7: SOFT TISSUES AND THE NECK

## 7.1 FACIAL LACERATIONS AND NECK WOUNDS

### Soft-tissue wounds

The head and neck, and particularly the face, are a frequent and exposed site for soft-tissue injury. Common causes include interpersonal violence, sporting injuries, mechanical falls, animal bites and road-traffic collisions. In oral and maxillofacial surgery, we see a LOT of facial lacerations and incised wounds. On a daily basis, a junior OMF surgeon will be in the emergency department (ED) suturing facial lacerations and treating patients with facial soft-tissue injuries. Technically speaking, a 'laceration' is defined as a break in the skin caused by a blunt force or shearing trauma and an 'incised wound' is caused by a sharp object or implement, such as a knife. However, in day-to-day practice it has become commonplace to call the majority of injuries 'lacerations', regardless of the aetiology.

The take-home message from this chapter is that regardless of how minor the injury may appear, a thorough ATLS approach to assessment is mandatory. It is common, even in seemingly mild injuries, to have underlying injuries to deep vital or bony structures. The drama from an actively bleeding facial laceration may be masking a much more serious injury and a judicious assessment will avoid potential complications later on.

### 7.1.1 SIMPLE SOFT-TISSUE LACERATIONS/WOUNDS

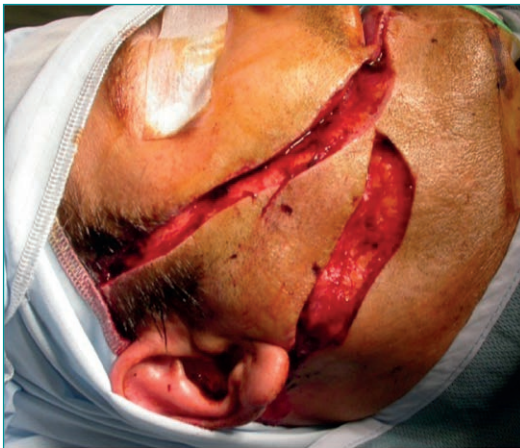In most instances, simple lacerations or wounds can be thoroughly washed, debrided and closed at the time of presentation and assessment – either under LA in the ED or sometimes requiring a GA in theatre. There are a number of factors that must be considered when deciding if a laceration is amenable to closure.

ALWAYS check the tetanus status of the patient, and if in doubt or in higher-risk/soil-contaminated wounds, give a tetanus booster (the BNF provides full guidelines for this). Even before you have examined the patient, the history of the mechanism of injury should guide your management. For example, if

a patient reports being ‘stabbed with a knife’, you should be asking what size was the knife, was it clean, did it have a straight or serrated blade, and so on. These are all factors that will impact the injury and management. Also ask specifically about risk of wound contamination – for example, trauma on a muddy sports field or a bite from a wild/unvaccinated animal – factors such as these may point you towards a course of prophylactic antibiotics, or an even more thorough wound washout under a GA. When you examine the wound, you may first need to clean it and the surrounding area to get a clearer view of the depth of penetration and surrounding soft-tissue injury or trauma to local structures.

### 7.1.2 DEEP SOFT-TISSUE INJURIES

When we start to talk about ‘deep facial injuries’ we are concerned about injuries to vital structures beneath the skin. Obviously, there are a lot of important anatomical structures within the face. Superficial blood vessels, such as the facial artery and vein, and superficial temporal vessels can cause significant bleeding. In deep facial lacerations/wounds, broadly speaking we are immediately concerned about the facial nerve and parotid duct. This is because these are structures that may need complex microsurgical reconstruction and the wound should be temporarily cleaned and packed first and closed at a secondary procedure.



*Figure 7.1: This patient suffered significant facial injuries as a result of interpersonal violence. The patient presented with facial paralysis, suggesting the facial nerve branches had been severed. Picture courtesy of Professor P. Brennan*

The location of the parotid duct can be identified using facial surface landmarks. If you draw an imaginary line from the tragus of the ear to mid-upper lip, the parotid duct lies in the middle third of this line. Deep wounds

in this region need examination inside the mouth to check that saliva is still discharging from the parotid-duct orifice – which as mentioned previously is found adjacent to the second maxillary molar.

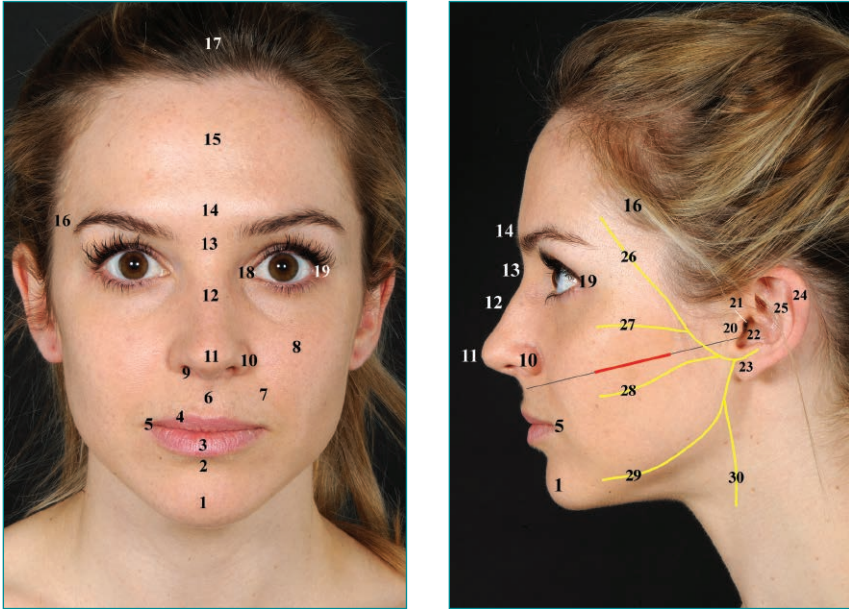
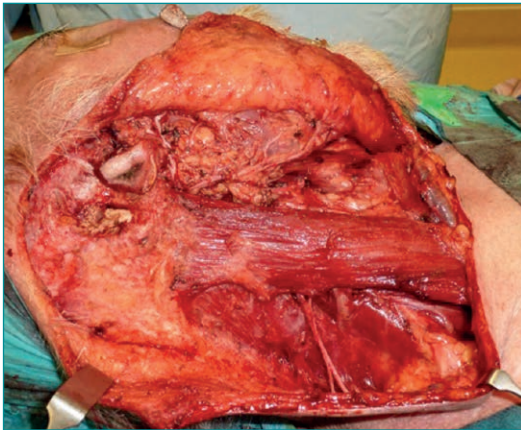


Figure 7.2: (a) Anterior view of surface anatomy of face. (b) Lateral view of surface anatomy of face, with representation of facial nerve (yellow line) and parotid duct (red line – middle third of line drawn from inferior tragus to mid-point of philtrum).

- |                                   |  |
|-----------------------------------|--|
| 1. Chin                           | 17. Scalp                                      |
| 2. Labio-mental groove            | 18. Medial canthus                             |
| 3. Vermillion of lower lip        | 19. Lateral canthus                            |
| 4. Vermillion border of upper lip | 20. Tragus                                     |
| 5. Oral commissure                | 21. External auditory meatus                   |
| 6. Philtrum                       | 22. Conchal bowl                               |
| 7. Naso-labial groove             | 23. Lobe                                       |
| 8. Cheek                          | 24. Helix                                      |
| 9. Nares (nostril)                | 25. Antihelix                                  |
| 10. Ala of nose                   | 26. Temporal branch of facial nerve            |
| 11. Nasal tip                     | 27. Zygomatic branch of facial nerve           |
| 12. Dorsum/bridge of nose         | 28. Buccal branch of facial nerve              |
| 13. Nasion                        | 29. Marginal mandibular branch of facial nerve |
| 14. Glabella                      | 30. Cervical branch of facial nerve            |
| 15. Forehead                      |  |
| 16. Temple                        |  |

The facial nerve needs to be examined *before* injecting local anaesthetic. All five divisions (temporal, zygomatic, buccal, marginal mandibular and cervical) should be examined and their function clearly documented in the patient's notes. Recall your anatomy? The cervical branch supplies the platysma muscle in the neck. As a rule of thumb, any potential facial nerve injury in front of a vertical line drawn through the lateral canthus of the eye is considered low risk – the reason being that in this region the nerve has divided into smaller branches, so potential injury is less serious and also any repair of such a small branch would be very difficult, if not impossible, even for the best microvascular surgeon around. A deep laceration posterior to this safe zone has a higher risk of cutting a named branch or even the trunk of the facial nerve and should therefore be examined more thoroughly. If in doubt, you should always have a low threshold for contacting a senior.



*Figure 7.3: This is not a trauma patient, but the picture shows the path of the facial nerve and also the accessory nerve. In cancer and trauma patients, OMF surgeons spend time finding and protecting these. Picture courtesy of Mr. M. Ethunandan*

### Penetrating neck injuries

In oral and maxillofacial surgery, we also accept referrals for penetrating neck injuries. Even with a lay appreciation of anatomy, it's clear to see that any penetrating injury to the neck (i.e. deep to the platysma muscle) has significant potential for injury to major neurovascular structures. Unlike lymph-node levels, the neck is divided into trauma zones 1–3, with different vital structures at increased risk in each zone:

- Zone 1 – From clavicles to cricoid cartilage
- Zone 2 – From cricoid cartilage to angle of mandible
- Zone 3 – From angle of mandible to base of skull.

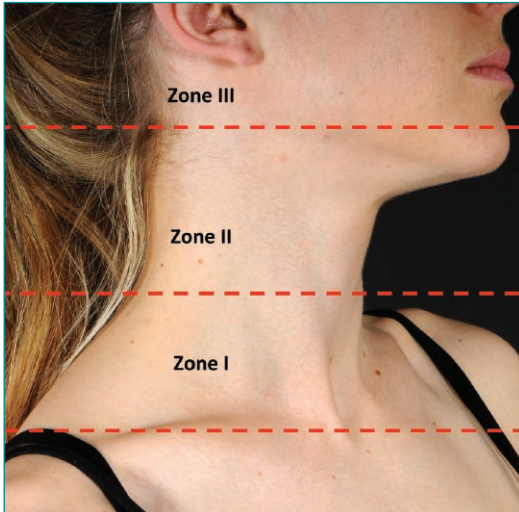
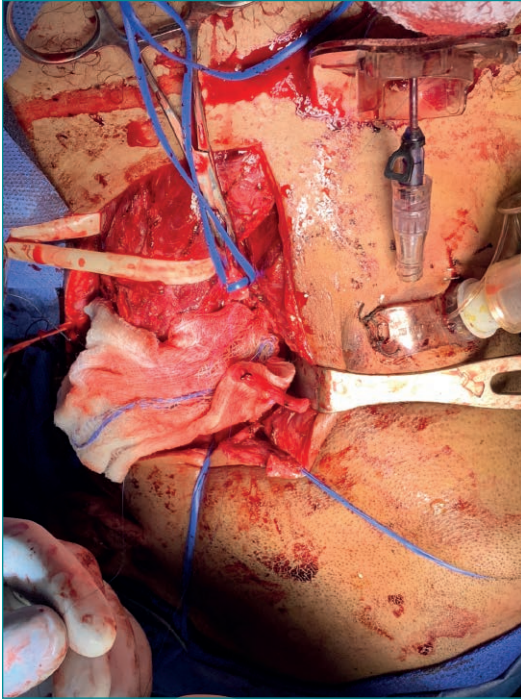


Figure 7.4: Lateral view of neck with markings for trauma zones I-III

If you are a junior trainee assessing a potential penetrating neck injury, then you should be calling for help immediately. While a slight oversimplification, any patient with 'hard signs' (unstable observations and active haemorrhage) of a vascular injury should go to theatre straight away, whereas clinical suspicion alone may warrant a CT angiogram first to assess potential vascular injury. Injury to the common carotid or internal carotid artery (which is less likely because, as the name suggests, this is deep to the external carotid) requires input from vascular surgeons.

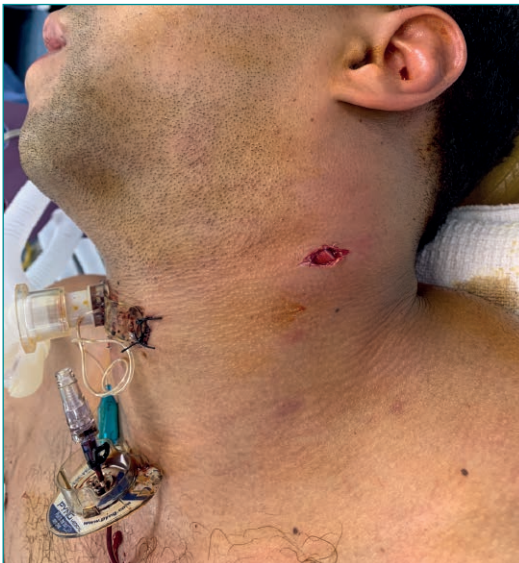

Figure 7.5: This patient presented with a stabbing to the neck. Whilst the wound only appears small, it is the damage to underlying structures and potential for bleeding in and around the neck that are of concern. Note that he has had a temporary tracheostomy placed to protect his airway. Pictures courtesy of Lieutenant Colonel Johnno Breeze



*Figure 7.6: As well as securing this patient's airway with a temporary tracheostomy, OMF surgeons had to isolate the carotid artery to manage the underlying haemorrhage. Pictures courtesy of Lieutenant Colonel Johnno Breeze*

### 7.1.3 BITES

Bites from dogs, cats and, yes, even humans are grossly contaminated and carry a significant risk of infection. In addition, animals such as dogs are capable of significant forces, so crush injuries and underlying skeletal injury should always be considered. Cats on the other hand (with their sharp teeth) are more likely to cause puncture-type wounds, which on initial examination may appear fairly innocuous, but in the depth of the wound there may be significant contamination.

The key to managing any form of bite is copious irrigation and debridement of the wound as required. Owing to the rich head and neck blood supply, if one is happy, primary closure of such wounds under a LA after a thorough washout is perfectly reasonable. However, a delayed approach can also sometimes be adopted, particularly if there is associated tissue loss. All bites should be given prophylactic antibiotics, and local hospital guidelines are available in such instances.

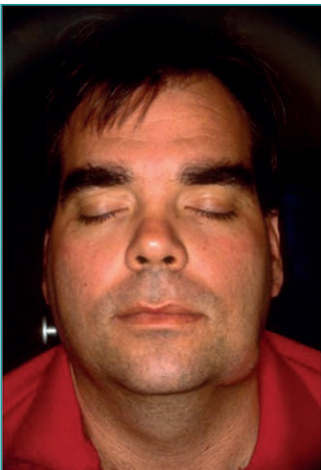
## 7.2 NECK LUMPS

Most hospitals in the UK have a head and neck lump clinic, to which patients will be referred from primary care with a lump or mass, requiring investigation. These clinics are often run jointly by OMFS and ENT. As a medical student, the concept of neck lumps can be overly daunting, especially when reading text books with lists and lists of possible causes. While you should be aware of all of these (especially for exams!), in clinical practice the common causes are much fewer. The majority of neck lumps seen in clinic will be related to lymph-node pathology, with the major concern being metastasis from undiagnosed head and neck cancer.

Assessment in a specialised clinic will comprise history, thorough examination and (if services allow) an immediate ultrasound scan (USS) with or without fine needle aspiration cytology (FNAC) for pathological assessment. The best approach to classifying the aetiology of a neck lump is to divide causes into inflammatory, congenital or neoplastic.

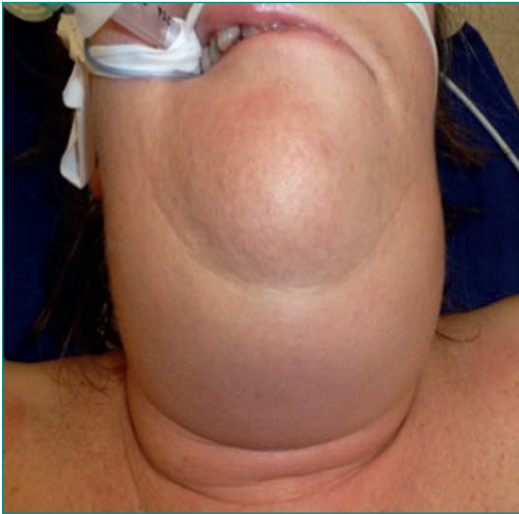### 7.2.1 INFLAMMATORY INCLUDING TISSUE SPACE INFECTIONS

Cervical lymphadenopathy secondary to infection is a common presentation. The head and neck have a wealth of lymph nodes (they can contain as many as 300 of the 800 or so nodes found throughout the body), which become enlarged, tender and palpable during times of infection. Common causes are: tonsillitis/peri-tonsillar abscess (quinsy), dental infection, pharyngitis, mastoiditis, otitis externa and otitis media, as well as skin pathology including acne.

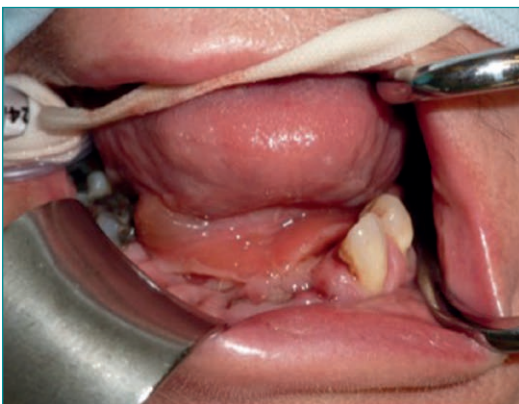

*Figure 7.7: This patient presented with a chronic dental sinus secondary to dental abscess. The patient presented with lymphadenopathy, which resolved once the offending tooth was removed. Picture courtesy of Mr. A. Sidebottom*

There are a number of ‘fascial’ layers within the head and neck that you should be aware of. Dental infections can cause extensive facial and neck swellings as the infection spreads unchallenged between these fascial spaces. There are a number of potential spaces, which are in continuity with the mouth, and if infection spreads into these channels they can cause trismus, dysphagia and even potential threat to the airway. Ludwig’s angina is a potentially fatal bilateral submandibular and sublingual cellulitis usually caused by a dental source. Patients often present with gross facial and neck swelling, difficulty swallowing their own saliva, a raised floor of mouth and looking systemically unwell – untreated, this can be rapidly fatal! Urgent intervention is required, usually in the form of a surgical airway and decompression of the submandibular and sublingual spaces, followed by a stay in the intensive care unit.



*Figure 7.8: This patient presented with bilateral submandibular and submental collections. This is called Ludwig’s angina. This poses an immediate threat to the airway and requires urgent surgical and anaesthetic intervention. Picture courtesy of Mr. M. Ethunandan*



*Figure 7.9: In Ludwig’s angina, the patient presents with a ‘raised floor of mouth’, with the tongue pushed up. They can also have dysphonia or altered voice and difficulty swallowing their own saliva. Picture courtesy of Mr. M. Ethunandan*

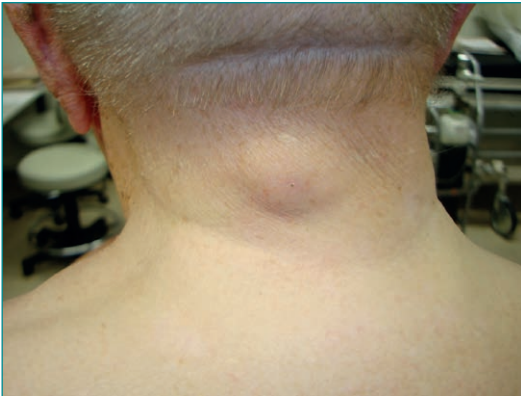

Viral infections such as paramyxovirus can cause bilateral facial swelling, often seen in children and known as mumps. Other infectious sources of cervical lymphadenopathy include TB, EBV (glandular fever) and HIV, to name but a few.

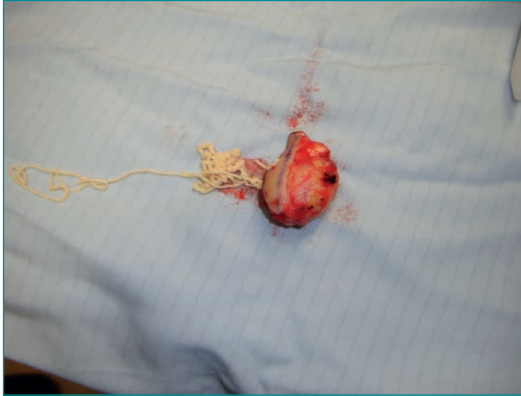### 7.2.2 CONGENITAL

There are a number of congenital masses found in the head and neck region which, whilst they often present in children, it is not uncommon to first identify in adult patients. For some adults, they will only become a problem via an incidental finding or when they become infected.

*Epidermoid cysts* – These are also commonly known as ‘sebaceous cysts’. Like dermoid cysts, they are caused by entrapment of embryonic derived ectodermal tissues within the dermis. This can be as a consequence of trauma or due to obstructed sebaceous glands (so in these cases they are not technically speaking ‘congenital’). Infected epidermoid cysts are common presentations to primary care. The overlying skin is erythematous and there is an associated swelling. Close examination reveals a ‘punctum’. These should be treated in the first instance with oral antibiotics and/or drainage of any collections under LA. Following this, they can be formally excised in an outpatient setting once the infection/inflammation has resolved.



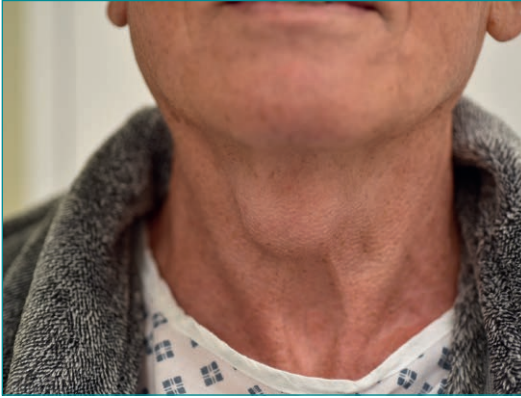*Figure 7.10: This patient presented with a mass in the nape of the neck. Notice a black mark in the centre of the lesion. This was a punctum. Picture courtesy of Mr. S. Walsh*



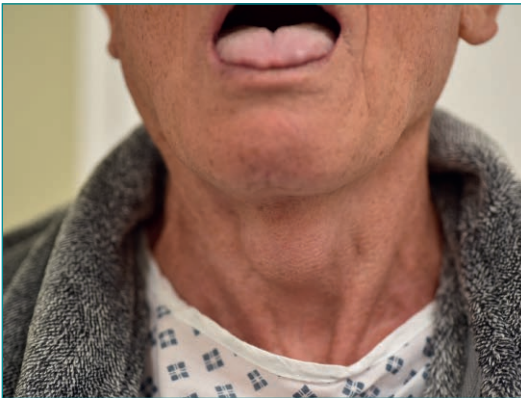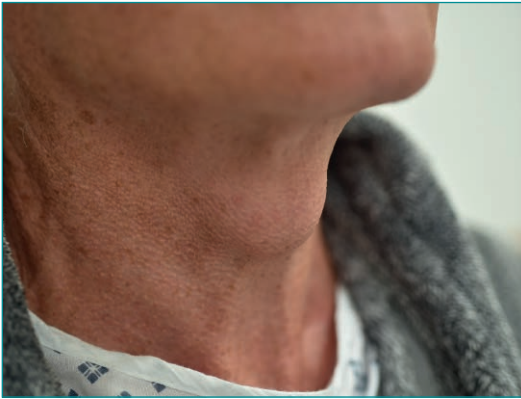*Figure 7.11: These are excised with an ellipse of skin enclosing the punctum. Here the surgeon has 'burst' the cyst to show the keratin found within the cyst cavity. Picture courtesy of Mr. S. Walsh*

*Dermoid cysts* – Very much like epidermoid cysts, dermoid cysts arise from entrapment of ectoderm during fusion of embryologic lines. Characteristically, however, they differ from epidermoid cysts in that they contain dermal appendages, for example hair follicles and sebaceous glands. Unlike epidermoid cysts, due to lines of fusion they are often found in the midline and paramedian regions, such as the midline of the neck and peri-orbital regions. These are again treated by surgical excision.

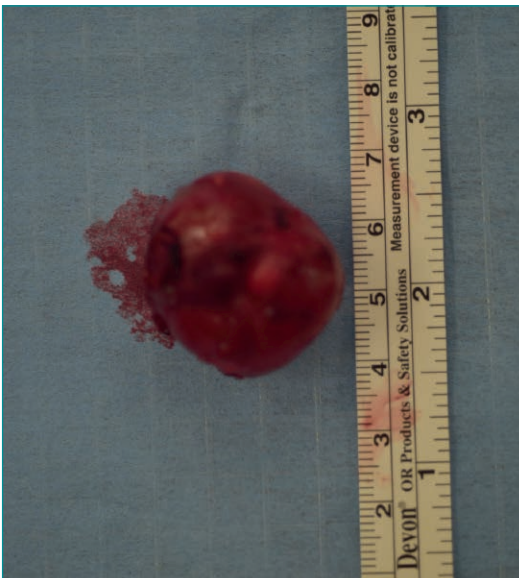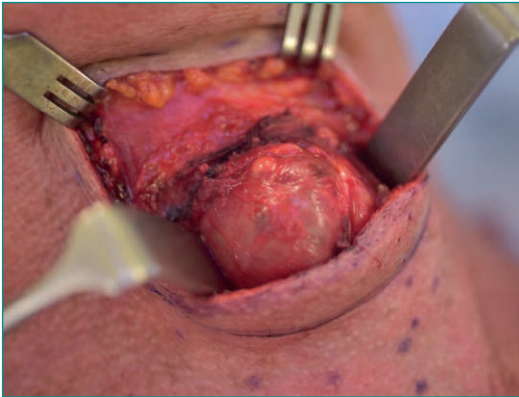
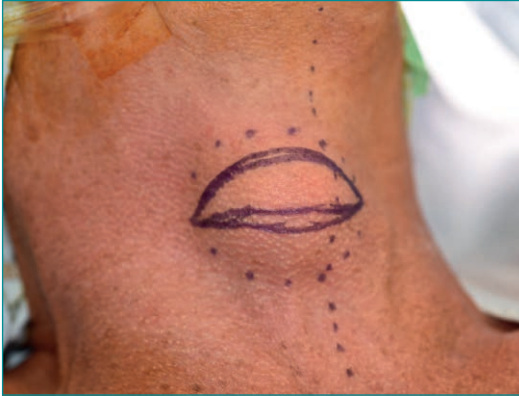*Thyroglossal cysts* – The thyroid gland originally develops in the foramen caecum, found at the junction between the anterior two-thirds and posterior one-third of the tongue. The developing thyroid gland descends via the thyroglossal duct, a tubular structure passing anterior to the hyoid bone, prior to arriving in its final position in the anterior neck. The thyroglossal duct normally disintegrates following the migration of the thyroid gland. Failure of this results in a persistent thyroglossal duct on which cystic change can occur. Thyroglossal duct cysts commonly occur in the first two decades. They most commonly present with a midline swelling that can occur anywhere along the path of descent of the thyroid gland, the bulk of which occur below the level of the hyoid bone. Notably, to distinguish thyroglossal duct cysts from other midline masses in the neck, ask the patient to protrude their tongue – this will cause upward movement, as they are almost always connected to the hyoid bone. Cross-sectional imaging and ultrasound guided FNAC can aid diagnosis. Management requires en-bloc excision of the thyroglossal cyst and tract, and some surgeons also remove the central part of the hyoid bone, to which it is commonly attached. This is called a Sistrunk procedure. Failure to completely excise the duct can lead to recurrence and, very rarely, malignant change.



*Figures 7.12 & 7.13: This patient presented with a midline neck mass. Pictures courtesy of Professor P. Brennan*



*Figure 7.14: When asking the patient to protrude the tongue, the mass moved up the neck. This is in keeping with a thyroglossal cyst, as they are often attached to the hyoid bone. Picture courtesy of Professor P. Brennan*



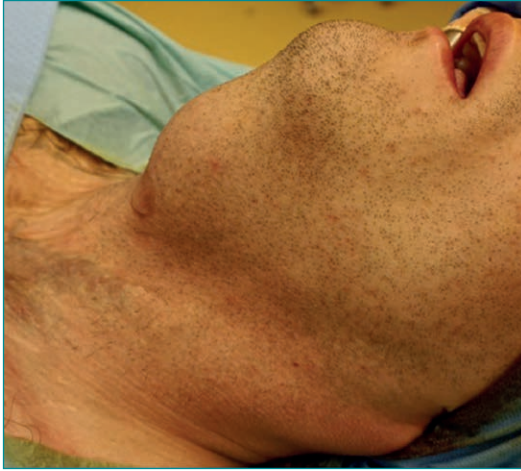Figures 7.15, 7.16 & 7.17: Thyroglossal cysts are removed in a procedure called a 'Sistrunk procedure'. This requires excision of the cyst and duct but also part of the hyoid bone in order to prevent recurrence. Pictures courtesy of Professor P. Brennan

*Branchial cyst* – You may recall from embryology that from weeks three to eight in intra-uterine life, there are five pairs of branchial arches. These give rise to the major structures of the head and neck.

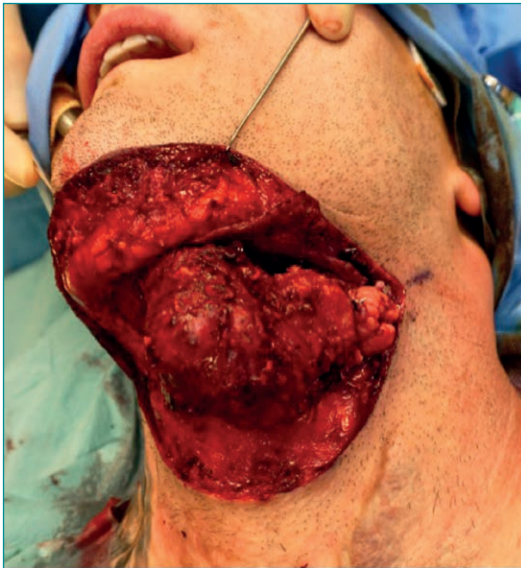The arches give rise to a number of branchial clefts, which are ectoderm lined and branchial, or pharyngeal pouches, which are endoderm lined. The mesoderm of the second branchial arch proliferates until it overlaps the third and fourth arches, leaving only a small ectoderm-lined sinus, known as the cervical sinus. This normally disappears with time; however, failure to involute or the persistence of cleft epithelia can result in branchial cysts, fistulae or sinuses. These present, most commonly, as neck swellings located along the anterior border of the sternocleidomastoid muscle, most commonly in the submandibular space; however, they can form anywhere from the parotid gland to the supraclavicular region. Third- and fourth-branchial-arch cysts are incredibly uncommon. They usually present as a soft, painless mass, but can become secondarily infected and are then tense with signs of inflammation.

When an adult over the age of 35–40 presents with a potential branchial cyst (most present much earlier in life), it is important to exclude the possibility that the mass could be metastatic carcinoma within cystic cervical lymph nodes, most notably from the tonsils and oropharynx, or even malignant change in a branchial cyst. Where there is diagnostic uncertainty, cross-sectional imaging and/or ultrasound guided FNAC can help delineate the cause. Management is in the form of surgical excision, and there is a fairly low rate of recurrence. Again, where there is any diagnostic uncertainty regarding potential malignant cause, they should be treated as malignant until proven otherwise.

*Vascular malformations* – The head and neck are an extremely vascular part of the body. As such, arteriovenous, capillary and lymphatic anomalies are reasonably common, either in isolation or as part of a systemic process or syndrome. Commonly, these lesions are investigated with ultrasound, MRI and/or CT. It is important to rule out any intracranial extension (which, if present, may put the patient at risk of catastrophic spontaneous intracranial haemorrhage). Treatment depends on cause: some lesions respond to beta-blockers (propranolol), whereas others may require cryotherapy, interventional radiology or even surgical removal.



*Figure 7.18: This gentleman presented with a submental swelling. Investigations including ultrasound and MRI revealed this to be an arteriovenous malformation. Picture courtesy of Mr. M. Ethunandan*



*Figure 7.19: Following preoperative CT-guided embolisation, the malformation was surgically removed. Picture courtesy of Mr. M. Ethunandan*

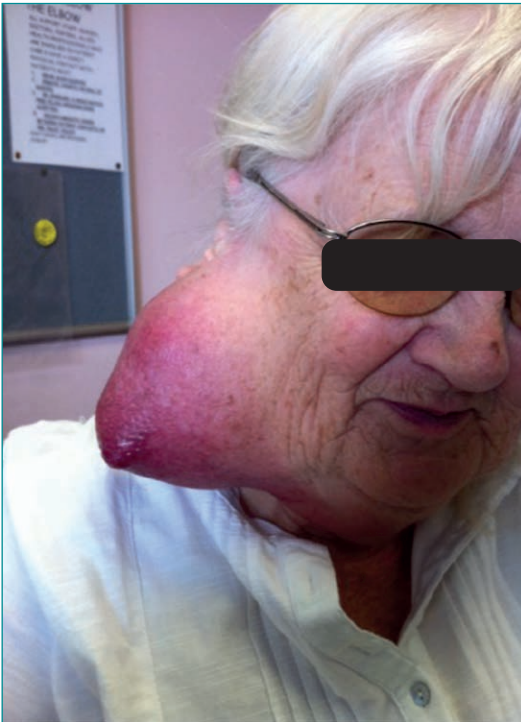### 7.2.3 NEOPLASTIC

Given that 300 of the total number of 800 or so lymph nodes reside in the head and neck, lymphoma often presents in the first instance as a neck mass. These are typically rubbery in consistency and usually multiple. Always ask patients about systemic symptoms such as loss of weight, night sweating and fever (B symptoms). Lymphoma is managed by oncologists but OMFS and ENT often help make the diagnosis, using US-guided core biopsies or even lymph-node biopsies in some cases.

A palpable malignant lymph node from a primary tumour in the head and neck is classically described as being hard or firm, progressing to a fixed mass with an irregular edge, and being larger than 1cm. This is due to the irregular growth of the cancer within the node and possible spread beyond its capsule into the adjacent tissue. In contrast, a reactive lymph node (secondary to infection/inflammation) exhibits hyperplasia of normal lymphoid tissue and is therefore contained within its capsule and presents as a firm but well-defined and mobile mass. A reactive lymph node will appear acutely and resolve as the infection subsides (i.e. within three weeks), whereas a malignant lymph node will present as a progressively enlarging mass over weeks or months.

It may be very difficult or impossible to discern between a reactive and neoplastic neck node. High suspicion for malignancy would warrant an USS with or without FNAC. In cases of low suspicion, reassessment in two-to-three weeks is reasonable, with an USS if the node is still present.

There are many other causes of neck lumps but these are outside the scope of this book. The main thing is not to get overwhelmed but to break things down into inflammatory, non-inflammatory, congenital and neoplastic (which can be primary or secondary) for starters!



*Figure 7.20: This lady presented with an extensive mass in the right neck/tail of parotid region. Picture courtesy of Professor P. Brennan*

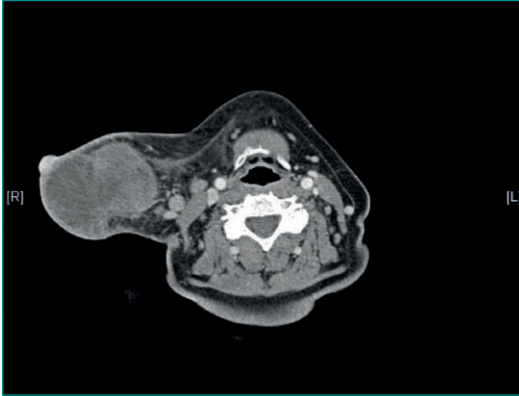


Figure 7.21: Cross-sectional imaging can be of huge diagnostic use. In this case, a CT with contrast was used to delineate the mass and give useful information of nearby major structures. Picture courtesy of Professor P. Brennan

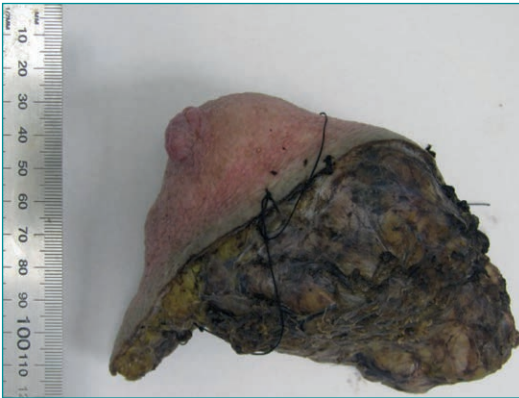


Figure 7.22: The mass excised. Picture courtesy of Professor P. Brennan

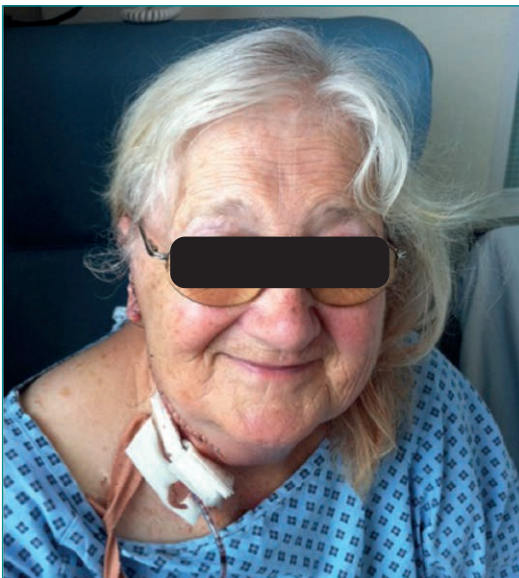

Figure 7.23: The postoperative result. Note that despite its proximity to the facial nerve, no branches or indeed the trunk were damaged. The patient had a House–Brackmann score of 1! Picture courtesy of Professor P. Brennan



## Thyroid masses

Patients presenting with a mass in the midline of the neck are an all-too-common referral to the neck lump clinic (thyroglossal cyst has already been discussed above). While ENT and general surgeons have historically managed diseases of the thyroid that require surgery, increasingly OMFS are also operating in these fascinating lesions.

Fortunately, the overwhelming majority of solitary thyroid masses are benign. As with any suspected thyroid condition, a targeted history concerning signs of hyper- and hypothyroidism should be elicited, as should questioning on dysphonia, stridor and dysphagia. A comprehensive neck examination should be performed, but one should also look for other features of extra-glandular disease manifestations.

Blood tests should be taken to check:

- TSH
- T3 Levels
- T4 Levels
- Antithyroid Peroxidase screen
- Antithyroglobulin screen.

In the first instance, ultrasound-guided FNAC can be hugely useful in arriving at a diagnosis. The use of radioisotope scanning can help differentiate between ‘hot’ and ‘cold’ nodules, and cross-sectional imaging such as CT and MRI can be used when assessing for metastatic disease.

*Thyroid goitre* – Most enlargements of the thyroid gland are non-toxic goitres. This is compensatory hyperplasia of the gland as a consequence of persistent stimulation of TSH receptors. This may be due to increased physiological demand, for example during pregnancy. It may, however, be secondary to iodine deficiency, which is oddly quite common, or Grave’s disease. If non-toxic, they can be managed by mere active surveillance.

*Papillary carcinoma* – In terms of solitary nodules within the thyroid gland, most are benign follicles. Of the thyroid nodules that are thyroid carcinomas, papillary carcinoma is the most common. This commonly affects young people between the ages of 30 and 40 years old. They have a good prognosis and are managed by either a lobectomy (if small), or total thyroidectomy and a neck dissection if cervical lymph nodes contain metastatic disease. Some surgeons advocate performing a central neck dissection, even if there is no evidence of metastasis. The growth of papillary carcinoma is also TSH driven and this is prevented by life-long administration of thyroxine to suppress TSH levels.

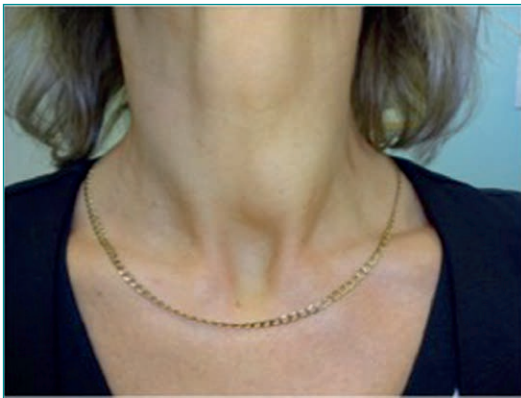*Follicular carcinoma* – This is the second most common thyroid carcinoma. It is commonly found in individuals over the age of 50. Unfortunately, fine needle aspiration is unable to distinguish between benign nodules and follicular carcinomas. As such, these patients undergo a diagnostic hemithyroidectomy. Where necessary, a completion thyroidectomy is then performed and radioactive iodine is given postoperatively. Unlike papillary carcinoma, follicular carcinoma spreads haematogenously and, as such, there is generally no need to perform a neck dissection. Such patients are again given life-long thyroxine.

*Medullary carcinoma* – This arises from parafollicular cells, which are normally responsible for the production of calcitonin. Up to one-third of medullary carcinomas are hereditary, being associated with multiple endocrine neoplasia (MEN) syndrome.

These are again treated with total thyroidectomy and neck dissection where required; however, unlike both papillary and follicular, medullary carcinoma is not sensitive to radioiodine or thyroxine.

*Anaplastic carcinoma* – While this is the rarest form of thyroid carcinoma, it is the most aggressive by far. It classically occurs in patients over the age of 60 years old and survival from the point of diagnosis is a matter of months. In most cases treatment is palliative.

There are also parathyroid tumours (which often cause hypercalcaemia) but they do not often present as neck lumps, and are diagnosed on blood tests and nuclear medicine scans.



*Figure 7.24: This lady presented with a midline neck mass which moved on swallowing, characteristic of thyroid masses. These can often be differentiated from thyroglossal cysts, which classically move 'up' with tongue protrusion. Picture courtesy of Mr. S. Walsh*

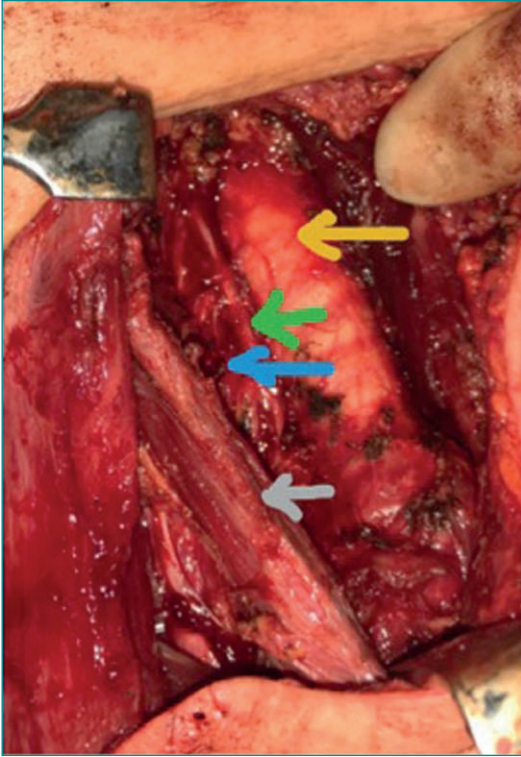


Figure 7.25: This is an intra-operative picture showing the number of structures closely related to the thyroid gland. Note that running in between the trachea (yellow arrow) and oesophagus (blue arrow) is the recurrent laryngeal nerve (green arrow). Picture courtesy of Mr. P. Alam



*A man having undergone the first stage of Sushruta forehead flap reconstruction of the nose following a dog bite.*

# CHAPTER 8: SKIN PATHOLOGY AND AESTHETIC SURGERY

## 8.1 SKIN CANCER

### 8.1.1 MALIGNANT MELANOMA

Skin cancer is extremely common. Many of us will have a friend, relative or personal experience of some form of skin cancer, so quite often these can be a talking point at social reunions! Skin cancers are generally divided into non-melanoma skin cancers (BCCs and SCCs) and malignant melanoma. While melanoma only represents 5% of skin cancers, it accounts for a significant majority of skin-cancer-related deaths. Sadly, despite public awareness and education, its incidence has doubled in the last 40 years.

#### Risk factors

Melanoma can develop in otherwise normal skin, or from pre-existing pigmented lesions. Like other forms of skin cancer, ultra-violet (UV) light exposure is considered the primary cause. However, unlike non-melanoma skin cancers, melanoma is perceived to be a consequence of intense sun exposure (burning is a key factor in particular).

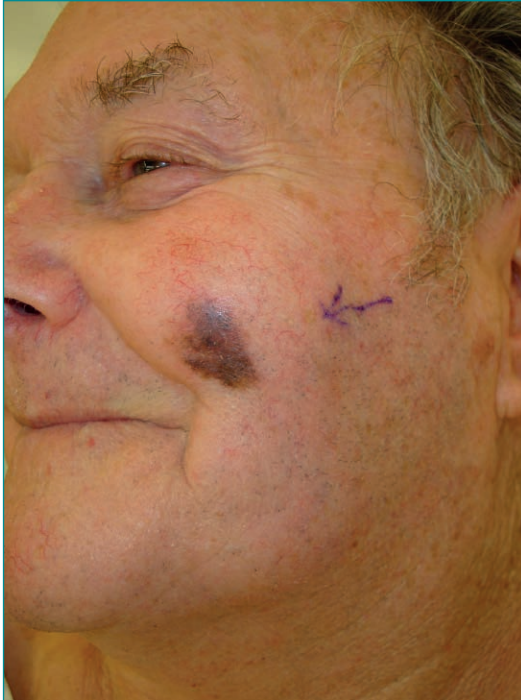The important risk factors to consider when taking a 'melanoma' history from anybody are as follows:

1. Pre-existing pigmented lesions
2. Age
3. Fair skin
4. Immunodeficiency
5. Family history.

#### Clinical features

On examination, melanoma can have some classic clinical features. Pigmented lesions especially can be risk-assessed using an ABCDE approach.

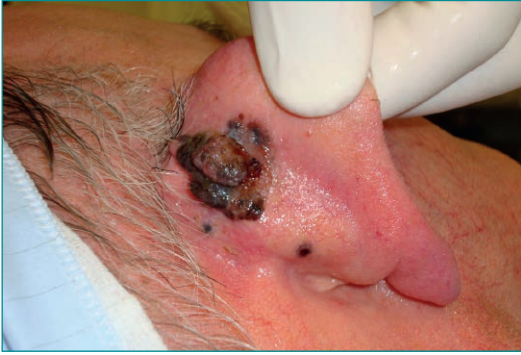- A - Asymmetry
- B - Irregular borders
- C - At least two different colours in the lesion
- D - Diameter >6mm
- E - Elevation of lesion



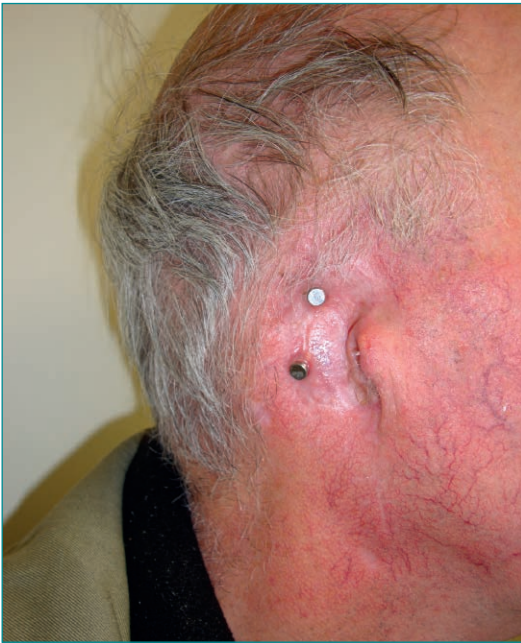*Figure 8.1: When assessing pigmented lesions, it is essential to use the ABCDE approach. Here, this suggested that the patient had a possible malignant melanoma. Picture courtesy of Mr. S. Walsh*

## Management

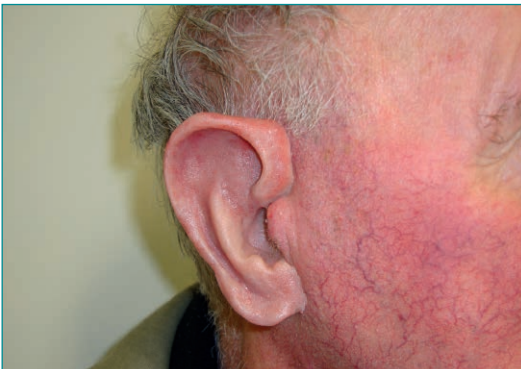When a melanoma is suspected, removal (excisional biopsy) with a margin of 2–5mm is advised. This provides a biopsy that represents the entire clinically visible lesion and therefore provides the best chance of an accurate diagnosis (whereas an incisional or ‘punch’ biopsy, which only samples part of the lesion, might miss a crucially important area of deeper invasion).



*Figure 8.2: This gentleman presented with a pigmented lesion behind the right pinna. This was confirmed as malignant melanoma. Picture courtesy of Mr. S. Walsh*



*Figure 8.3: In order to potentially cure the patient, excisional biopsy meant pinnectomy, or removal of the ear. In order to provide reconstruction, titanium implants were placed into the temporal bone. Picture courtesy of Mr. S. Walsh*



*Figure 8.4: Once the implants had fully osseointegrated, a prosthesis was made by the laboratory which would be anchored onto the implants. Picture courtesy of Mr. S. Walsh*

## Staging

Today, it is established practice to measure the ‘Breslow thickness’, that is the thickness in mm measured from the **granular** layer of the epidermis to the deepest layer of identifiable tumour cells. This helps both stage the patient and provide a subsequent margin for further (definitive) wide local excision at a later date.

Melanoma has a tendency of metastasising to distant sites, so CT of the lungs, abdomen, pelvis and brain is often recommended by the MDT.

## Sentinel lymph node biopsy

Sentinel lymph node biopsy is widely considered to be the most accurate means of staging regional lymph nodes in melanoma. This is a staging procedure to check for regional spread – it is not a treatment. It involves the administration of a radioisotope tracer prior to nuclear imaging on the same day as surgery. Furthermore, blue dye is also injected into the site of the skin tumour. Using nuclear imaging and a specialised probe, the ‘sentinel node’ (the first draining node(s) from the anatomical region of the tumour) can be removed through a small neck incision and histologically checked for possible tumour cells. In this way, the stage of the tumour, from the point of view of regional spread, can be better assessed.

## Treatment

Despite the advances in modern medicine, surgical excision of melanoma (at an early stage) is still the most effective treatment for malignant melanoma in terms of an attempt at complete cure. The excisional margin is determined by the Breslow thickness of the lesion. Melanoma management is always discussed at an MDT, with input from dermatologists, oncologists, pathologists, radiologists and surgeons (such as ENT, OMFS and plastics).

When there is regional lymph node disease in the head and neck, confirmed with ultrasound-guided FNAC or core biopsy, or by sentinel lymph node biopsy, a neck dissection with or without a superficial parotidectomy is performed, depending on the original location of the melanoma (for example, an anterior scalp or cheek melanoma can spread to the parotid gland nodes, hence it being included in the surgery). However, the presence of regional spread is a worrying sign and significantly reduces the chance of cure.



## Metastatic disease

The presence of distant metastatic disease provides a poor prognosis. Treatment is delivered by a number of means to control the disease in a palliative manner but will not allow cure. A number of modalities can be used which can include surgery, chemotherapy, immunotherapy and radiotherapy, or a combination of these. Treatment will always be discussed and agreed by the multi-disciplinary team (MDT).

## 8.2 NON-MELANOMA SKIN CANCER (NMSC)

Non-melanoma cancers are the overwhelming majority of skin cancers arising in the head and neck – these are basal cell carcinomas (BCC), the commonest skin cancer, and squamous cell carcinomas (SCC). Fortunately, providing they are caught early, both are quite curable, though SCC does have a risk of metastasis to the regional lymph nodes. Nevertheless, it's important to remember that somebody who has had a skin cancer (regardless of complete cure) is at high risk of having similar cancers in the future and therefore requires a vigilant monitoring process for life. The key risk factors to consider when you suspect non-melanoma skin cancer are:

- Chronic exposure to UV light (burning is a concern but unlike melanoma, it is the long-term history of UV exposure that is thought to be more relevant)
- Immunosuppression
- Genetic conditions
- Fair skin
- Premalignant conditions or lesions such as Bowen's disease (a scaly-like skin rash that histologically appears as carcinoma in situ) or actinic keratosis (also known as 'solar keratosis'; found typically in sun-bearing areas such as the forehead, scalp, ears, nose, cheeks and chin).

## Presentation

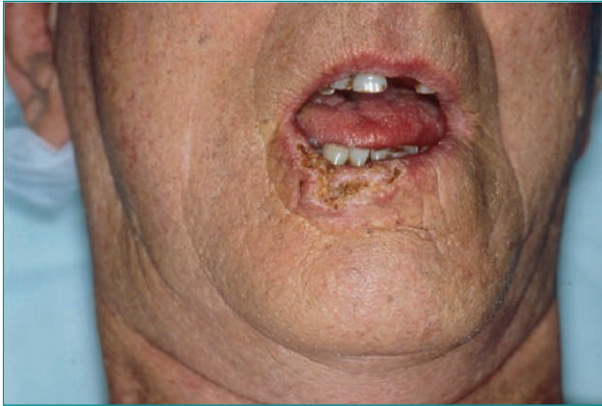### *Basal cell carcinoma (BCC)*

This is the commonest skin cancer and we see a lot of it, particularly in the southern parts of the UK where there is more sunshine. BCCs are usually slow growing and they do not metastasise, but their common name, 'rodent ulcer', confirms that they can be locally destructive. In large lesions, we sometimes have to remove the nose, or ear, and in cases of extreme neglect, even the orbital contents. There are numerous clinical forms of BCC such as cystic, nodular, morpheic and superficial BCC. But most importantly, these

can be divided into low risk – nodular and superficial BCCs – and high risk – morphoeic/infiltrative, micronodular or baso-squamous.

### **Squamous cell carcinoma (SCC)**

Squamous cell carcinomas typically present as an indurated nodular lesion that may ulcerate, with a classically ‘punched-out’ appearance (unlike the more ‘pearly rolled edge’ of an ulcerating BCC); nevertheless, the two may often look similar clinically but differ histologically. These tumours can also present with a classic ‘keratin horn’, which is frequently mistaken by elderly patients and even healthcare professionals as dry ‘crusty’ skin. Other ‘crusty’ (flatter) patches of skin are more commonly actinic keratoses but even these have the potential to transform into a SCC. Like melanoma, SCC will be discussed at a skin MDT for best patient care.



*Figure 8.5: This gentleman presented with a crusting ulcer with ‘rolled’ edges. This was later confirmed as cutaneous SCC. Picture courtesy of Mr. A. Sidebottom*

### **Diagnosis**

Diagnosis of either form of non-melanoma skin cancer (NMSC) is usually achievable on clinical grounds alone, so many lesions are biopsied with an excisional biopsy (using an appropriate margin) as a one-stop diagnosis and treatment. However, when in doubt, histological confirmation is achieved before definitive treatment, and this is achieved using either an incisional biopsy (of which punch biopsy is a type) or exfoliative cytology (skin scrapings – although this is relatively uncommon and not as diagnostically informative as a formal incisional biopsy).

## Staging

If the patient presents with no evidence of cervical lymph node involvement, then there is no need of cross-sectional imaging. However, when nodal involvement is suspected, cross-sectional imaging of the neck and parotid should be performed and an FNA (or even better, a core biopsy) should be performed on clinically palpable enlarged nodes.

## Treatment

### BCC

Excision of the lesion is widely accepted as the gold standard. Depending upon the presence of high-risk features, the lesion is usually excised with a 4–5mm margin of normal tissue, which results in the clearance of disease in 95% of lesions. Exceptions are larger, infiltrative and morpheic BCCs, which, by their nature, can make it difficult to establish surgical margins. As a result, wider margins are used to increase the chance of complete excision. Other management strategies are:

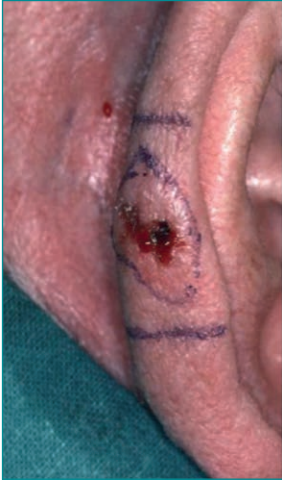- Mohs micrographic surgery (step-by-step excision over several hours, using immediate frozen section histology to establish whether the tumour has been completely excised)
- Destructive techniques (e.g. curettage, cryosurgery or laser)
- Non-surgical
  - Photodynamic therapy
  - Immune modulators
- Radiotherapy.

### SCC

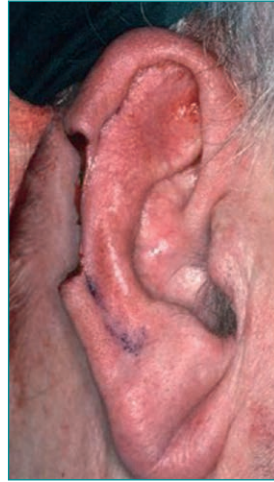Following MDT discussion, surgical excision is the treatment of choice, with a 95% clearance being achieved with a margin of 4mm for low-risk lesions, and a 6mm margin required for high-risk lesions. Other possible approaches include Mohs surgery, curettage and cautery or cryotherapy (the latter two used only by experienced practitioners).

### *Regional metastatic disease*

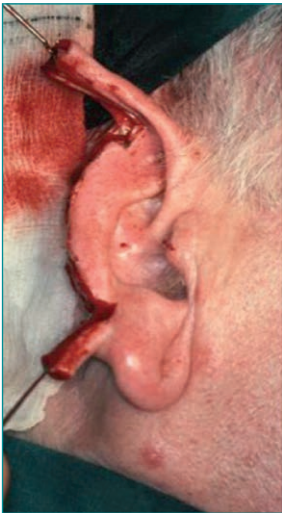This occurs in around 5% of cutaneous SCCs. If there is regional lymph node involvement and no evidence of distant metastatic spread (e.g. to the lungs) then surgery in the form of a neck dissection with or without a superficial parotidectomy (depending on the site of the tumour) is the treatment with the best chance of cure, potentially alongside postoperative (adjuvant) radiotherapy.



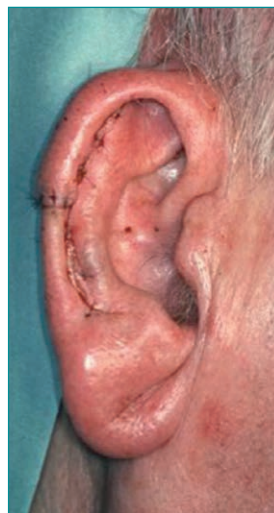*Figure 8.6: This patient presented with a lesion on the right pinna. Diagnosis can be challenging, as SCC can closely resemble BCC. In these instances, incisional biopsy can be useful. Picture courtesy of Professor P. Brennan*



*Figure 8.7: Excision of the lesion with a recommended margin can result in unsightly defects. Picture courtesy of Professor P. Brennan*



*Figure 8.8: An OMF surgeon is also trained in reconstructive surgery. Such techniques were employed here. Picture courtesy of Professor P. Brennan*



*Figure 8.9: The final result! Picture courtesy of Professor P. Brennan*

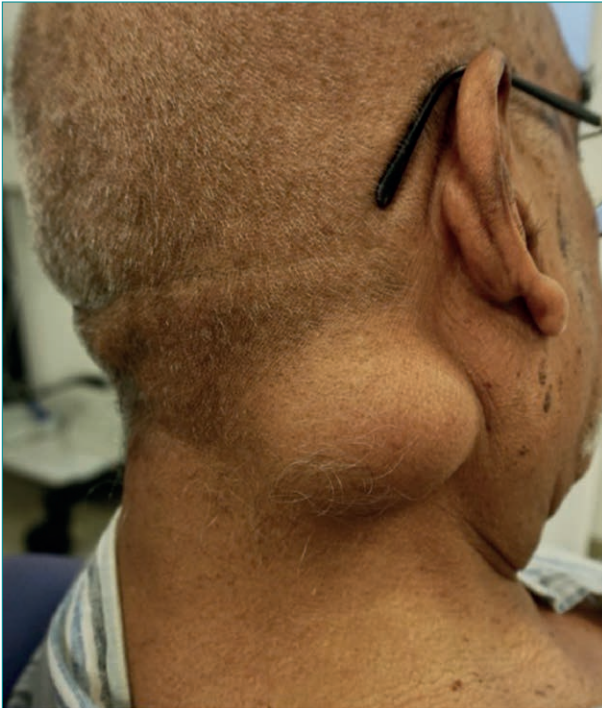## 8.3 BENIGN SKIN TUMOURS

### *Keratocanthoma*

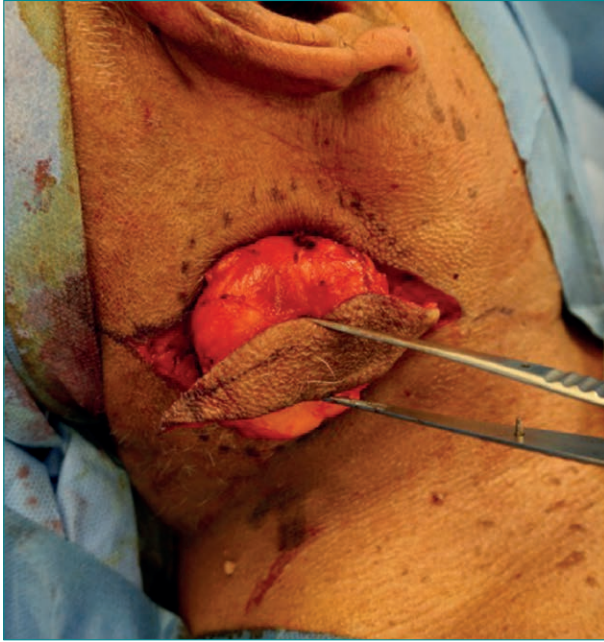Keratocanthomas mimic cutaneous squamous cell carcinomas in appearance, but most notably, these regress with time. Despite this, their diagnosis can be incredibly challenging clinically. As such, histological assessment is in the patient's best interest and they are generally treated by excision.

### *Lipoma*

A lipoma is a benign fat tumour that can occur in the subcutaneous tissues as well as elsewhere in the body, including the gut and within skeletal muscle, for example. They are completely harmless and slow growing. Most notably, on examination they will feel dough-like and mobile within the skin. Quite often the patient will report it's been there for many years and has slowly grown over that time. Treatment is by simple excision. Sometimes an ultrasound can be useful to give an idea of size or proximity to surrounding structures. If you are going for honours, remember Dercum's disease – multiple lipomas – which classically presents in obese, post-menopausal women.



*Figure 8.10: This gentleman presented with a slow-growing, soft lump in the posterior neck. Ultrasound was highly suggestive of a lipoma. Picture courtesy of Mr. M. Ethunandan*



*Figure 8.11: The lump was removed. As these are slow-growing, benign masses, they often act as skin expanders. Upon removal, any excess or redundant skin should also be excised. Picture courtesy of Mr. M. Ethunandan*

## 8.4 AESTHETIC SKIN SURGERY

Humans are social animals. Our faces are complex structures that play an important role in how we engage through social interaction. How we perceive the way we look also has impacts on our own psychology and can affect us in profound ways. While many of the problems you have read about in this book look to manage and correct functional problems – a bleeding nose, a fractured jaw or a growing tumour, it is not unusual to meet patients who don't have functional problems. Instead, they are not happy with the appearance of their face, whether that be due to a previous injury, a product of ageing or simply something about their facial appearance that they feel to be unappealing.

Facial aesthetics is a broad field and perhaps one where the craft and judgment of an oral and maxillofacial or plastic surgeon are particularly highlighted. Aesthetics can be impacted in a number of ways and at a number of levels. Sometimes they are limited to the cutaneous layer. For example, patients may be concerned about how scars from previous operations have healed. As you have read, we often work hard to hide facial scars in areas of the face that naturally heal well, but sometimes, particularly in traumatic injuries, this is not possible. This can leave often quite conspicuous scars in aesthetically sensitive areas. Sometimes, the subcutaneous tissues and fat beneath the

skin can be affected, leading to asymmetry or the appearance of swellings or depressions. Muscle weakness or atrophy, either through direct injury, ageing or disrupted nerve supply, can compromise aesthetics, as can any change in the underlying bony or cartilaginous contour.

Regardless, our knowledge of facial anatomy and physiology becomes very useful as we try to address these patients' concerns – what is it exactly that is concerning the patient and what are the specific underlying causes of the aesthetic problems? The key tenets of any medical assessment remain fundamental – a thorough history and examination, carefully unpicking the key concerns and worries, are vital. Then, importantly, once these have been explored, we consider how best to correct the issue. There are highly varied options either to correct the underlying problems or to mask them in a way that no longer appears unaesthetic. The most straightforward way to think of these is as non-surgical or surgical treatments.

Non-surgical treatments are things like botulinum toxin injections, dermal fillers or resurfacing procedures. Botulinum toxin type A (or 'Botox', which is actually a brand name) works by disrupting the transmission of impulses at the neuromuscular junction and thus, when carefully injected into specific sites, can serve to decrease the dynamic skin creases by paralysing some of the muscles of facial expression and reducing dynamic wrinkling. Common areas that are injected are the frown lines over the nasal bridge and forehead, and the crow's feet over the lateral aspects of the orbits.

Dermal fillers are injectable substances that are used to fill out the deep grooves around the face and smooth out problematic wrinkles. Resurfacing techniques tend to involve removal of the very superficial layers of problematic areas, and allowing the new formation of healthier tissue.

There tends to be lots of overlap between different surgical options, but they can largely be thought of as '*-plasties*', 'lifts' and 'grafts or implants'.

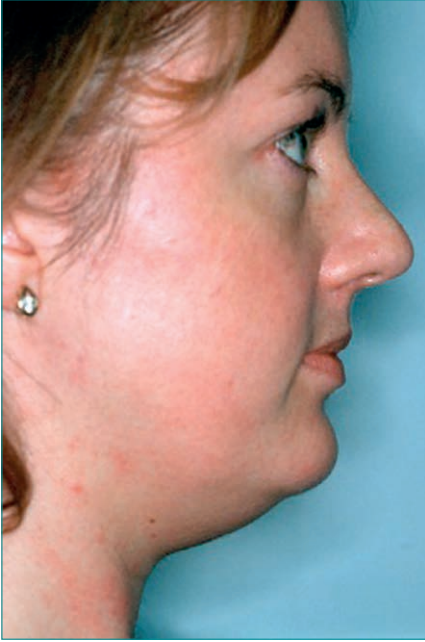'*Plasties*' are a group of terms that highlight how a surgeon alters the appearance of a particular area. For example, a blepharoplasty modifies the appearance of the upper or lower eyelids; a rhinoplasty reshapes the nose; an otoplasty can alter the shape of the ear; while a genioplasty changes the shape or size of the chin. These often involve alterations in different elements of these structures such as skin, underlying fat or bone. Importantly, there are nuances and complexities involved with each of them and huge variation in how they are performed from surgeon to surgeon.

Whether secondary to an ageing face, or due to traumatic muscle or nerve injuries, over time the tissues of the face can begin to sag, droop or wrinkle

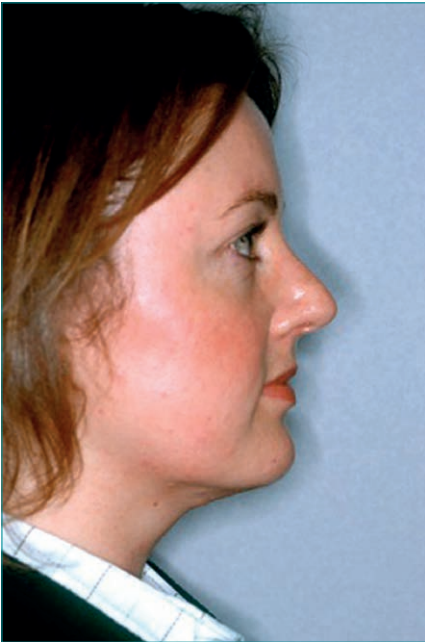due to the loss of underlying muscle tone. In these situations, various different *lifting* procedures may benefit patients. The wrinkles in the forehead or eyebrow can be addressed using brow lifts. These can be done either directly, with an incision in the forehead itself (hidden in the creases or the hairlines), or using endoscopic techniques which use several small, inconspicuous incisions instead. In both cases, the skin, fat and muscles are pulled up, stretched and anchored to give a rejuvenated appearance. Other lifting procedures include the rhytidectomy – or face lift – where again, the surgeon's knowledge of facial anatomy (for example, the same anatomy encountered when performing parotid gland surgery) becomes vital. In these procedures, we make use of the SMAS layer – the superficial musculo-aponeurotic system – that serves to interconnect many of the intricate muscles of facial expression. We know that it is the muscle action of the face that leads to wrinkles, so simply stretching the skin is perhaps not the best way to rejuvenate the face. However, we can make a hidden skin incision and raise a facial skin flap then, importantly (and with care, because the facial nerve lies just deep to this layer), we can then dissect the SMAS layer, lift it and remove any excess and re-anchor it – thus stretching out the muscle layer. We can then drape the skin over this, which is a far more effective way to reduce wrinkling and rejuvenate the patient's facial appearance.

In some situations, stretching or reshaping what is already there is perhaps not appropriate, and an area may need further augmentation. Similar to dermal fillers, autogenous (i.e. the patient's own) fat can be harvested, for example from the abdomen, groin or thigh. This can either be a block of dermal fat which can be placed en-bloc in the recipient site or a liquefied form of fat transfer: lipo-suctioned fat is centrifuged and then reinjected to a particular region to bulk out a contracted scar, or to fill a defect caused by an untreated frontal bone fracture, for example. Other defects, particular those caused by underlying bony defects, can be masked with synthetic graft material, bone grafts or cartilage. Of course, many of these techniques are used alongside each other, and choosing which work well together can take many years to fully appreciate!





*Figure 8.12: This patient presented with concerns of an ageing face. Picture courtesy of Mr. A. Sidebottom*



*Figure 8.13: She underwent a neck lift and submental lipectomy. This resulted in a more youthful appearance. Picture courtesy of Mr. A. Sidebottom*

*Following surgery and chemotherapy, this man with facial osteosarcoma became a qualified psychiatric nurse and proud father.*



# CHAPTER 9: ORAL AND MAXILLOFACIAL SURGERY – CAREER AND RESEARCH OPPORTUNITIES

## 9.1 INTRODUCTION

After browsing through the rest of this book, we hope you will have come to realise that OMFS is a diverse and interesting specialty. Despite being perceived as ‘niche’ and unique (given the need for dual qualification in both medicine and dentistry), it actually encompasses a huge range of conditions and surgical treatments that merge with ENT, plastic surgery, trauma, and orthopaedics and dentistry. The surgery can include cleft, craniofacial, orthognathic and dentoalveolar surgery, skin, salivary gland, major head and neck cancer and free-flap reconstructions, plating facial fractures and exploring a patient’s neck after penetrating neck trauma. As such, it straddles the divide between medicine and dentistry and is the primary referral source for dentists and from GPs for all problems of the face, mouth, neck and jaws. OMFS sub-specialties include:

- Oral surgery
- Trauma
- Head and neck oncology and reconstruction
- Salivary gland surgery
- Paediatric OMFS
- Craniofacial and deformity
- TMJ
- Cleft
- Facial aesthetics.

Arguably, in no other specialty are you exposed to, and trained in, the plethora of soft- and hard-tissue skills, across both paediatric and adult patients, and benign and malignant disease.

Historically, OMFS was a dental specialty borne from the necessity for dentists and oral surgeons to enter the hospital setting to treat facial trauma. As of 1995, all OMF consultant surgeons required dual qualification and the 2008 Post Graduate Medical Education and Training Board (PMETB) review provided further evidence for the requirement of both medical and dental

qualifications. OMFS is one of the 10 UK surgical specialties and as such is regulated by the General Medical Council (GMC).

Despite being a medical specialty, the uptake of OMFS to the medical school curriculum has been slow (hence the requirement for this book!). While the OMFS workforce was almost exclusively made up of ‘dental-first’ surgeons who completed a medical degree after working as an OMFS SHO, over the past 10–15 years there has been a changing tide, with around half of newly appointed OMFS specialty registrars (StRs) now being ‘medicine-first’ trainees. This reflects the fact that of the relatively few undergraduate and postgraduate medics in the UK who gain exposure to OMFS, a significant proportion love it so much that they will go on to get a second degree in dentistry and become an oral and maxillofacial surgeon! The balance of trainee backgrounds between ‘medicine first’ and ‘dentistry first’ creates a rich and diverse specialty workforce.

## 9.2 CAREER PATHWAY

What often confuses medical students or trainees interested in OMFS as a career is the training pathway – in other words, when to do the second degree. All trainees of course need to undertake foundation training to become GMC registered, but there seems to be an even split between trainees who return to dental school immediately and those who wait to do core surgical training and then make the jump. It often comes down to exposure to OMFS during medical school and foundation training, in addition to local opportunity. Before making the decision to return to undergraduate dental training, you need to have experienced OMFS, ideally in an OMFS post. Several units now offer foundation or SHO-grade OMFS posts for singly qualified medical trainees.

It seems reasonable to make the point that OMFS has a longer training pathway, given the additional time spent returning to dentistry. Fortunately, however, shortened three-year dental courses are available and there is the option to achieve core surgical training competencies in one year rather than two, in addition to the advent of run-through OMFS training that starts at ST1. Those who have already completed core surgical training (CST) through the standard route and passed the MRCS examination can enter OMFS training at ST3 level. Furthermore, the higher surgical training element (ST3 onwards) is only five years until completion, whereas other specialties (such as plastic surgery or general surgery, for example) require six years. Whilst a few (perhaps two or three) extra years in training overall seems daunting as a medical student, it could be considered insignificant when compared to

the 40-year career most of us have to look forward to! A guide to the OMFS training pathways can be found on the BAOMS website ([www.baoms.org.uk](http://www.baoms.org.uk)) at [www.baoms.org.uk/professionals/careers\\_in\\_omfs.aspx](http://www.baoms.org.uk/professionals/careers_in_omfs.aspx)

### 9.3 RESEARCH

Despite the potential for a slightly longer training pathway, OMFS trainees still endeavour to undertake higher degrees to follow an academic surgical career. With the plethora of potential sub-specialties listed above, the scope for research is vast. Because of the historic roots in dentistry (pardon the pun), much of the academic work was previously undertaken within dental schools alone. However, with the vast advances in the scope of surgery performed (including complex head and neck and craniomaxillofacial procedures), OMFS was formally recognised as a surgical specialty within medicine rather than dentistry in 1994, and now the academic base of OMFS has expanded into medical schools and allied groups, for example genomics research. OMFS has a particularly strong reputation for research into head and neck cancer and reconstruction – leading on national and international clinical trials, and with several units within the UK undertaking important basic science and translational research.

The academic pathway within OMFS is not dissimilar to those of other surgical specialties, with options to complete academic clinical fellowships (ACF) and academic clinical lectureships (ACL) during training. However, you don't need a higher degree to get involved in OMFS research: from student to registrar, there are abundant opportunities to undertake potentially high-impact research and get some decent publications to your name. Oral and maxillofacial surgeons recognise the importance of furthering their specialty and, having completed two degrees, are optimally placed to do so.

If you are interested in research then go to the BAOMS website ([www.baoms.org.uk](http://www.baoms.org.uk)) and check out the Junior Trainees' Group (JTG) and the Maxillofacial Trainee Research Collaborative (MTReC), in addition to the UK Society of Oral and Maxillofacial Academic Surgeons' website.

## INDEX

- Actinic keratosis 123, 124  
 Alveolar bone graft 80, 81  
 Anaplastic carcinoma 116  
 Anastomosis 74, 97  
 Angular cheilitis 67  
 Anterior open bite 4, 46  
 Anterolateral thigh flap 73  
 Apicectomy 78  
 Arteriovenous malformation 111–12  
 Arthrocentesis 55  
 Arthroscopy 55  
 Atypical facial pain 93
- Basal cell carcinoma 25, 38, 119, 123–6  
 Bell's palsy 95  
 Bilateral sagittal split osteotomy 52  
 Bimaxillary osteotomy 52  
 Black hairy tongue 67  
 Blepharoplasty 129  
 Bony exostosis 6, 70  
 Botulin toxin type A 129  
 Bowen's disease 123  
 Branchial arches 111  
 Branchial cyst 111  
 Breslow thickness 122  
 Burning mouth syndrome 93
- Candidiasis 65, 66  
 Carcinoma in situ 63, 123  
 Cellulitis 106  
 Cerebrospinal fluid 17  
 Cervical lymphadenopathy 6, 7, 61, 85, 105, 107  
 Cervical sinus 111  
 Chronic hyperplastic candidiasis 65  
 Cleft lip 34, 41, 79–81  
 Cleft palate 34, 41, 79–81  
 Conchal cartilage 39  
 Cranial nerves 6, 14, 92  
 Craniosynostosis 19  
 Cricothyroidotomy 10  
 Crow's feet 129  
 CT scan 9, 21, 43, 44
- Dental caries 8, 77
- Dental implants 38, 77, 78  
 Dental sinus 69, 105  
 Dentoalveolar surgery 77–8, 133  
 Denture-induced hyperplasia 69  
 Dermal fillers 129, 130  
 Dermoid cyst 107, 108  
 Distraction osteogenesis 19, 53, 81
- EBV 67, 71, 107  
 Enophthalmos 21  
 Epidermoid cyst 107, 108  
 Epistaxis 35, 46  
 Erythroplakia 63, 67  
 Excisional biopsy 7, 69, 120, 121, 124  
 Exodontia 77  
 Extracapsular dissection 88
- Face lift 97, 130  
 Facial nerve 15, 16, 41, 55, 83–8, 96, 97, 100–2, 114, 130  
 Facial palsy 95–7  
 Facial reanimation 97  
 Fascial layers 87, 106  
 Fat transfer 130  
 Fibroepithelial polyp 69  
 Fibula 73, 76, 78  
 Fine needle aspiration cytology (FNAC) 86, 105, 108, 111, 113, 115, 122  
 Follicular carcinoma 116  
 Foramen caecum 108  
 Fordyce spots 66  
 Forehead flap 15, 39, 118  
 Frey's syndrome 88, 91  
 Frontal bone 2, 13, 14, 17–18, 47, 130  
 Frontal sinus 14, 17, 30  
 Fronto-nasal duct 14, 17  
 Fronto-nasal prominence 41
- Genioplasty 53, 129  
 Geographic tongue 66  
 Guillain-Barré 95
- Hairy oral leukoplakia 67  
 Hemithyroidectomy 116  
 Herpes Zoster 94

- HIV 67, 107  
 House–Brackmann scale 95, 114  
 Human papilloma virus (HPV) 71  
 Hypoglobus 21, 22, 23
- Impaction 77–8  
 Incisional biopsy 63, 64, 71, 120, 124, 126  
 Joint replacement 55
- Keratin horn 124  
 Keratocanthoma 127  
 Keratosis 63, 65–6, 123, 124
- Laceration 2, 11, 95, 99–100, 102  
 Lateral canthotomy 10  
 Le Fort 4, 46–7, 52  
 Leukoedema 66  
 Leukoplakia 63, 67  
 Lichen planus 64–5  
 Lichenoid reaction 65  
 Lipoma 127  
 Ludwig's angina 106  
 Lymph node 6, 61, 71–2, 86, 102, 105, 111, 112–13, 122–3, 125  
 Lymphoma 112
- Malignant melanoma 7, 119–22  
 Median rhomboid glossitis 67  
 Medullary carcinoma 116  
 Minor salivary glands 69, 83, 90  
 Mohs micrographic surgery 38, 125  
 MRI 54, 72, 86, 93, 111, 112, 115  
 Mucocele 69, 90  
 Mucosal melanoma 64, 67
- Nasal packing 35–6  
 Nasal splint 33  
 Naso-orbito-ethmoidal fractures 31  
 Nasolacrimal duct 30  
 Neck dissection 68, 72, 73, 115, 116, 122, 125  
 Neck lumps 7, 72, 105–17
- Obstructive sleep apnoea 50  
 Occipitontal radiographs 9, 37, 49  
 Occlusal radiograph 89  
 Oculo-cardiac reflex 22  
 Operculum 77  
 OPG 8, 37, 43, 54, 56, 76
- Ophthalmoplegia 24  
 Oral submucous fibrosis 64, 71  
 Orbital compartment syndrome 24  
 Oroantral communication 37  
 Orthognathic surgery 50, 80, 81, 133  
 Osteotomy 33, 52, 76  
 Otoplasty 129
- PA mandible 8, 43, 56  
 Papillary carcinoma 115, 116  
 Paramedian forehead flap 15  
 Paranasal sinuses 29, 30  
 Parathyroid tumours 116  
 Pemphigoid 5, 62  
 Pemphigus 5, 62  
 Penetrating neck injuries 102–3, 133  
 Peri-tonsillar abscess 105  
 Pericoronitis 77  
 Photodynamic therapy 125  
 Pinnectomy 121  
 Pleomorphic adenoma 85, 88  
 Post herpetic neuralgia 94  
 Punch biopsy 120, 124
- Radial forearm free flap 73, 74, 75  
 Radiotherapy 25, 72, 86, 123, 125  
 Ramsay Hunt syndrome 95  
 Ranula 69–70, 90–1  
 Reactive lymph node 113  
 Recurrent aphthous stomatitis 62  
 Relaxed skin tension lines 26–7, 39  
 Retrobulbar haemorrhage 10, 24  
 Rhinoplasty 33, 53, 80, 81, 129  
 Rhytidectomy 130
- Salivary glands 68, 69, 83–90, 133  
 Sebaceous cyst 107  
 Sentinel lymph node biopsy 72, 122  
 Septoplasty 33, 81  
 Shingles 94  
 Sialogram 88  
 Sialolithiasis 88  
 Sinusitis 38, 92  
 Sistrunk procedure 108, 110  
 SMAS 87, 130  
 Solar keratosis 123, 124  
 Space-occupying lesion 93  
 Speech and language therapy 19, 79, 81

- Squamous cell carcinoma (SCC) 25, 38, 61, 68–9, 71–3, 75, 119, 123, 124–6, 127
- Staging 71–2, 122, 125
- Static reanimation 97
- Stickler syndrome 79
- Stridor 115
- Superficial parotidectomy 84, 88, 122, 125
- Synovial fluid 54
  
- Telecanthus 31
- Temporomandibular joint 3, 8, 40, 41, 54–7, 92
- Temporomandibular joint dysfunction 54–6, 57, 92
- Tetanus 99
- Thyroglossal 108–10, 115, 116
- Thyroid gland 69, 108, 115–17
  
- Thyroidectomy 115, 116
- TNM system 72, 86
- Torus 70
- Tracheostomy 10, 73, 103, 104
- Trauma zones 102–3
- Trigeminal neuralgia 92–3
  
- Ulcers 6, 60–2, 63, 68, 95, 123, 124
- Ultrasound 72, 79, 86, 105, 108, 111, 112, 115, 122, 127
  
- Varicella-zoster virus 94
- Vascular malformation 111
- Velopharyngeal insufficiency 81
  
- White eye orbital floor fracture 23
- Wisdom teeth 3, 34, 77





# ORAL AND MAXILLOFACIAL SURGERY

An Illustrated Guide for Medical Students and Allied Healthcare Professionals

*Looking for a fulfilling career in a unique specialty that combines aspects of head and neck surgery, facial plastic surgery, facial orthopaedics and dentistry?... Then look no further.*

*Oral and Maxillofacial Surgery: An Illustrated Guide for Medical Students and Allied Healthcare Professionals* is the definitive and only resource specifically for undergraduate medical students, brought to you by an author team of both trainees and consultants on behalf of the British Association of Oral and Maxillofacial Surgeons (BAOMS). This book revolves around key anatomical regions and uses a unique “fireside chat” approach that makes easy reading. It simplifies and demystifies basic aspects of oral and maxillofacial, and head and neck surgery, by covering the basics of clinical examination of the face and mouth as well as managing pathology of the skull, facial skeleton and paranasal sinuses, jaws, mouth, salivary glands, neck and facial skin. It is highly relevant to all medical undergraduates but especially those who would like to simply ask the question, “What exactly is oral and maxillofacial surgery” and “Is this a potential career for me?”. In addition to prime educational content that is practically relevant to the undergraduate medical curriculum, the reader will gain a clearer insight into the career pathway in the UK, the unbelievable breadth of the specialty and the myriad opportunities that it can provide.

**Robert Isaac**, Specialist Registrar in Oral and Maxillofacial surgery (OMFS) in the Wessex Deanery, UK  
**Arpan S. Tahim**, Specialist Registrar in Oral and Maxillofacial Surgery (OMFS) in the London Deanery, and an Honorary Clinical Lecturer at UCL Medical School, UK

**Karl F.B. Payne**, Specialist Registrar in Oral and Maxillofacial surgery (OMFS) in the West Midlands Deanery, and NIHR Clinical Lecturer at the University of Birmingham, UK

**Alexander M.C. Goodson**, Consultant Maxillofacial Surgeon at Queen Alexandra Hospital, Portsmouth, UK

**Peter A. Brennan**, NHS Consultant with a personal chair in Surgery in recognition of his extensive research and education profile

